

Retrospective Analysis of Ponticulus Posticus in Orthodontic Patients Visiting a Private Dental College in Chennai

Vigneshwaran Ravichandran¹, Vivek Narayan², Dhanraj Ganapathy^{3*}

¹Saveetha Dental College, Saveetha Institute of Medical and Technical sciences (SIMATS), Saveetha University, Chennai, India, Email : 151701038.sdc@saveetha.com

²Department of Oral Medicine and Radiology, Saveetha Dental College, Saveetha Institute of Medical and Technical sciences (SIMATS), Saveetha university, Chennai, India, Email : viveknarayan@saveetha.com

³Professor & HOD, Department of Prosthodontics, Saveetha dental college, Saveetha Institute of Medical and Technical sciences (SIMATS), Saveetha university, Chennai, India, No.162, Poonamallee High Road, Chennai-600077, India, Email : dhanraj@saveetha.com

Abstract

Introduction : Ponticulus posticus is an anomaly located on the first cervical vertebrae which can be appreciated on the lateral cephalogram that is mostly neglected by the dentist. Ponticulus posticus is seen commonly in the lower primates. The aim of this study is to assess the prevalence of ponticulus posticus and its relation with Gender.

Materials And Methods : A sample of 100 patients Lateral cephalogram were retrieved, Each digital radiograph was inspected for the presence and absence of ponticulus posticus and the results were statistically analysed.

Results : Among the 100 patients, 35 % were Male and 65 % were Female, 33 % were less than 15 years old, 54 % were 15 to 25 years old, 12.5 % were 25 to 35 years old and 1 % were more than 35 years old. The ponticulus posticus was partially present in 16 % patients and absent in 84 % patients.

Conclusion : Ponticulus posticus is not an uncommon anomaly. If such an anomaly is discovered or suspected, it must be recorded in the patient's medical record and a professional consultation sought. As a result, the lateral cephalogram should be considered one of the primary screening tools for finding abnormalities and pathology in the cervical spine. therefore lateral cephalogram should be carefully examined to check for the presence of this anomaly before screw placement in the lateral mass of the atlas to avoid vertebral artery injury.

Keywords: Chennai, patients, analysis

DOI: 10.47750/pnr.2022.13.S04.131

INTRODUCTION

In clinical orthodontics, the lateral cephalogram is the most common diagnostic radiograph. Cephalometric tracings, on the other hand, typically omit the cervical spine area shown in lateral cephalograms. Although the cervical vertebrae maturation evaluation and its modified version, the cervical vertebrae maturation index (CVMI), are now widely used to interpret the development potential of young children [1]. In order to detect pathology, insufficient attention is made to the radiological anatomy of this region. A routine lateral cephalogram can reveal significant cervical spine pathology [2, 3]. Because "the eye sees what the mind understands," one of the goals of this article is to teach physicians and radiologists how to "see" the cervical spine and recognise deviations from normal structure. Ponticulus posticus is a defective bony bridge between the posterior section of the superior articular process and the posterolateral region of the superior edge of the posterior arch of the atlas. Its Latin name means "small posterior bridge." The normal atlas is a ring-shaped structure made up of two lateral masses linked by a short anterior arc and a longer posterior arch. It is the widest cervical vertebrae with its anterior arch approximately half the laminae of other vertebrae correlate to the posterior arch. A broad groove for the vertebral artery and the first cervical nerve can be found on its upper side. A bony arch may grow in 1–15 percent of the population, transforming this groove into a foramen through which these structures travel. The ponticulus posticus is the name for this bony arch [4]. Ponticulus posticus has been called pons posticus, arcuate foramen, foramen arcuale, retroarticular vertebral artery ring, Kimmerle abnormality, foramen atlantoideum, foramen sagitale, canalis arteriae vertebralis, and retroarticular canal of the atlas in the past [5–8] as long as the posterior arch. Because the majority of people with ponticulus posticus are asymptomatic, the clinical importance of this

diagnosis is debatable [9]. According to several studies, patients with ponticulus posticus have a low risk of having negative effects following cervical modifications due to its presence [10]. Migraine without aura [11], chronic tension type headache [12], vertigo, diplopia, and neck pain are among symptoms that may be connected with ponticulus posticus [13]. Ponticulus posticus has even been linked to vertebral artery compression, vertebro-basilar insufficiency, and even vertebral artery dissection. It must also be considered when the cervical spine is immobilised with lateral mass fixation in C1. During C1 lateral mass screw implantation, Young et al., observed that mistaken the ponticulus posticus for a broad posterior arch of the atlas could result in vertebral artery damage [14].

Although we are not directly involved in the treatment of cervical spine anomalies, we do have a responsibility as healthcare providers to document any such discoveries that may be relevant to the patient's overall health. We need to study the morphological aspects and the prevalence of this aberration because of its growing clinical importance. The lateral cephalogram is an effective screening technique for this condition.

Many studies have shown an association of ponticulus posticus with migraine. Because ponticulus posticus is intimately related to the atlanto-occipital membrane and this membrane, in turn is attached to the dura mater, small tensions exerted on the dura causing posterior circulation ischaemia and cervicogenic headache, which in turn results in excruciating pain in migraine. Its prevalence has been reported to be between 5.14 and 37.83% in the western population. Radiographically, Miki et al., have classified ponticulus posticus into three types:

Full type - complete bony ring

Incomplete type - some portions of bony ring are defective

Calcified type- linear or amorphous calcification

There appear to be very few studies on the prevalence or morphological characteristics of ponticulus posticus in an Indian population. Our team has extensive knowledge and research experience that has translated into high quality publications [15-34]. With this background, the present study was intended to investigate the prevalence and morphological features of ponticulus posticus and to identify any possible gender and age predominance with the prevalence of ponticulus posticus in an Indian population comprising patients reporting to private dental college in Chennai.

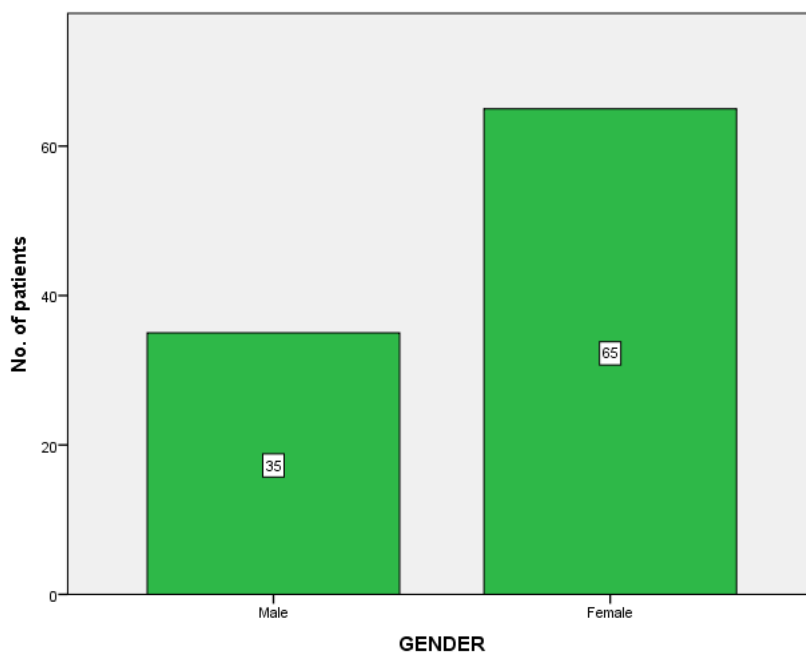
Materials And Methods

The study was done in Saveetha Dental college, Chennai. The study was approved by the ethical committee of the institution and it was carried out in the Department of Oral Medicine and Radiology. All the procedures were in accordance with ethical standards. Lateral cephalograms were retrieved from the archives and examined for ponticulus posticus. The study population was Indian (Dravidian) in origin belonging to Tamilnadu. Lateral cephalograms with poor visualization of the posterior arch of the atlas due to overlapping of the mastoid process or the occiput were excluded. Patients who reported congenital anomalies such as cleft lip and palate were not included in the study. Patients with other syndromic conditions involving the craniofacial region were also excluded. The images were viewed on a flat screen TFTLCD monitor (Thin Film Transistor-Liquid Crystal Display) with a resolution of 2906 x 2304 pixels in JPEG (Joint Photographic Experts Group) format with 24-bit grayscale. Each radiograph was carefully inspected for the presence of a ponticulus posticus and whether it was complete or partial. During initial examination, all lateral cephalograms were observed independently by two of the authors. All the data were entered in Microsoft Excel 2007 and subjected to statistical analysis. Chi square test was used to analyze the differences between males and females regarding the presence of ponticulus posticus. 100 lateral cephalograms were analysed.

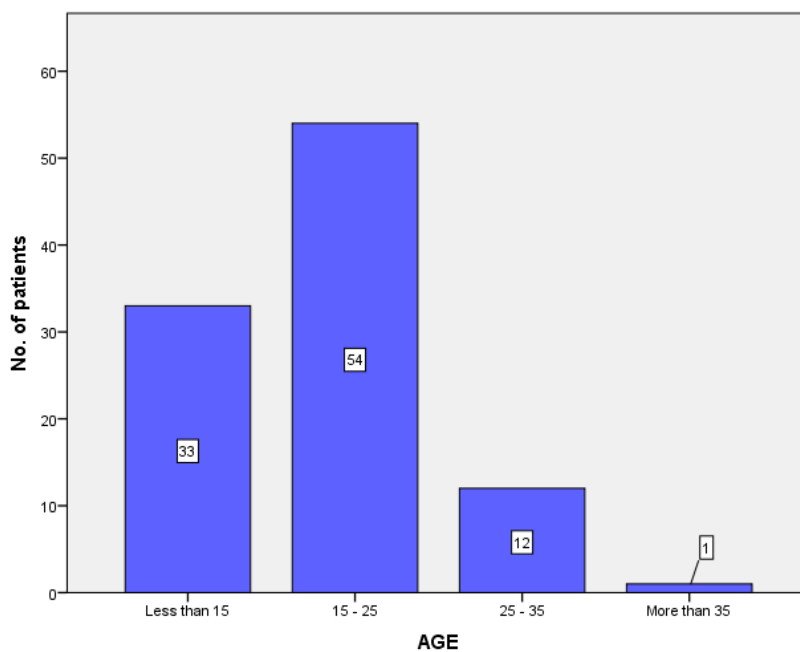
Results

Among the total 100 patients 35% were male and 65% were Female. 33% were less than 15 years old, 54% were 15 to 25 years old, 12% were 25 to 35 years old and 1% were more than 35 years old.

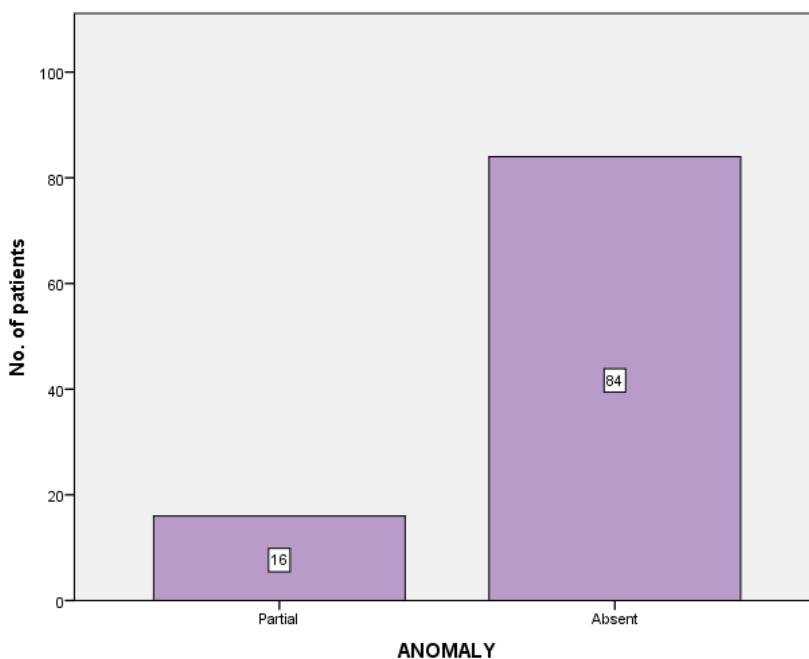
The ponticulus posticus was partially found in 16% of cases and absent in 84% of patients.



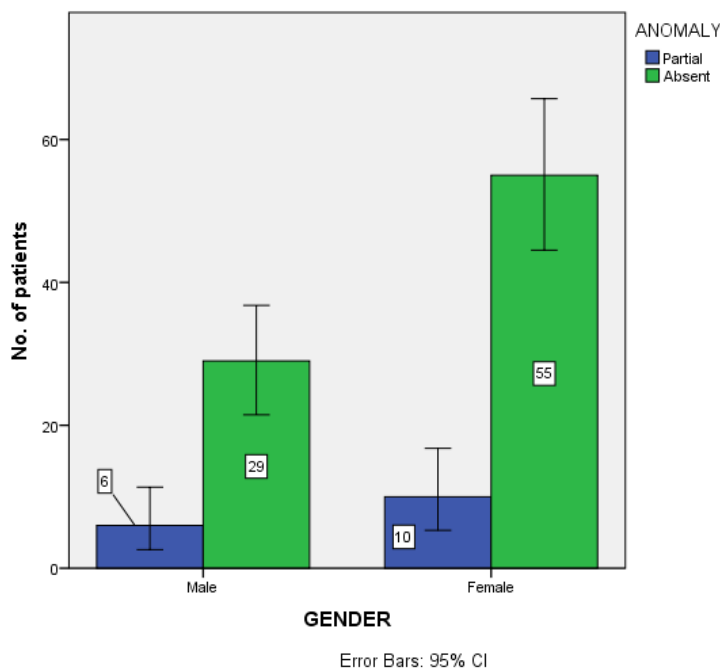
Graph 1 : The bar graph represents the Gender of the patients . The horizontal axis represents the Gender of the participants and the vertical axis represents the No. of patients .



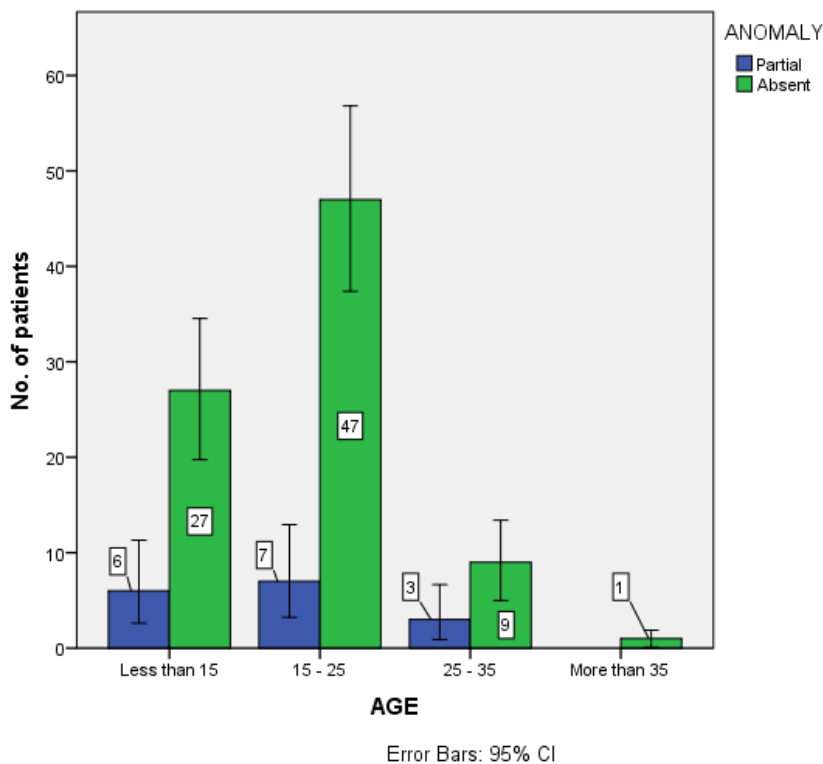
Graph 2 : The bar graph represents the Age group of the patients . The horizontal axis represents the Age group of the participants and the vertical axis represents the No. of patients .



Graph 3 : The bar graph represents the Presence of Anomaly [Ponticulus Posticus] . The horizontal axis represents the Partial presence or absence of Ponticulus Posticus and the vertical axis represents the No. of patients .



Graph 4 : The bar graph represents the comparison of Gender of the patients and the presence of Anomaly [Ponticulus Posticus] . The horizontal axis represents the Gender of the patients and the vertical axis represents the Number of patients . The colour Blue represents the Partial presence of Ponticulus Posticus and the colour Green represents the Absence of Ponticulus Posticus.



Graph 5 : The bar graph represents the comparison of Age of the patients and the presence of Anomaly [Ponticulus Posticus]. The horizontal axis represents the Age group of the patients and the vertical axis represents the Number of patients. The colour Blue represents the Partial presence of Ponticulus Posticus and the colour Green represents the Absence of Ponticulus Posticus.

Discussion

The prevalence of ponticulus posticus has been estimated to be between 5.1 % and 37.8 % in the western population [14, 35]. In radiological investigations, complete ponticulus posticus was found to be between 2.6 % and 14.3 %, and in osteological research, it was shown to be between 3.4 % and 15 % [36]. In our study, 2.95 % of the participants had entire ponticulus posticus. Female predominance [37] has been described more frequently, and our analysis shows a similar pattern. Cervical spine anomalies are more common in cleft lip and palate patients, according to numerous research.

V Sharma et al [38] identified a prevalence of complete ponticulus posticus of 4.3 % in Indian Orthodontic patients, which is greater than ours (2.95%), and they also showed male (5.33 %) predominance over female (3.76 %) in the population research. Complete ponticulus posticus was found in 2.8 % of males and 3.1 % of females in our study. The disparity could be explained by the fact that the populations in both research came from different places.

The results showed that the majority of the patients were Female and 15 to 25 years old. 6 % of Male patients have partial ponticulus posticus and 10 % of Female patients have partial ponticulus posticus. The ponticulus posticus was absent in 29 % Male and 55 % Female. The chi-square p value was statistically significant.

6 % of patients less than 15 years old have partial ponticulus posticus, 7 % of patients 15 to 25 years old, 3 % of patients 25 to 35 years old also have partial ponticulus posticus. The chi-square p value was statistically significant.

The prevalence of ponticulus posticus was reported to be around 15.8% in a study done on Caucasians by Kendrick et al [39], which is slightly higher than ours. This disparity could be attributable to the study groups' ethnic diversity. Given the serious consequences of neglecting this defect during cervical spine surgery and other cervical spine procedures, as well as the ease with which it can be prevented if diagnosed correctly, the ponticulus posticus should be found on routine lateral cephalograms.

Leonardi R et al [40] recently published a study that found that calcification of the atlanto-occipital ligament should be considered one of the key criteria for diagnosing neurofibromatosis type 1. Furthermore, because there is a link

between migraine, chronic tension headache, and the presence of the ponticulus posticus, both of these orofacial pain syndromes are considered as comorbid with TMJ disorders [41, 42].

Future Scope

Since our study was retrospective, we did not know about the pain status of the patients; so, more studies are needed to be done especially on symptomatic patients to further prove this correlation.

Conclusion

Ponticulus posticus is not an uncommon anomaly, therefore lateral cephalogram should be carefully examined to check for the presence of this anomaly before screw placement in the lateral mass of the Atlas to avoid vertebral artery injury. If this anomaly in lateral cephalogram is detected/suspected, a three dimensional imaging modality such as CBCT or CT scan is needed for that purpose.

In conclusion, the study revealed that ponticulus posticus is a prevalent ailment among Indians. Because this aberration has been linked to orofacial pain, such as migraine, more research should be done on diverse populations with bigger sample numbers, particularly on symptomatic patients, to confirm this link. If ponticulus posticus is discovered during routine radiography evaluation, it should be documented in the patient's health record, and if the patient is symptomatic, additional study should be sought.

Acknowledgement

The authors would like to acknowledge the support rendered by the Department of Oral medicine and Radiology & Saveetha dental college and hospitals and the management.

Author Contribution

All the authors contributed equally to the study

Source Of Funding

The present project is supported/funded/sponsored by Saveetha Institute of Medical and Technical Sciences, Saveetha Dental College and Hospitals, Saveetha University Kumaran TV center and Furnitures, Attur, Salem.

Conflict Of Interest

The author have no conflict of interest

REFERENCE

1. Farman AG. Panoramic Radiology: Seminars on Maxillofacial Imaging and Interpretation. Springer Science & Business Media, 2007.
2. Baccetti T, Franchi L, McNamara JA. The Cervical Vertebral Maturation (CVM) Method for the Assessment of Optimal Treatment Timing in Dentofacial Orthopedics. Seminars in Orthodontics 2005; 11: 119–129.
3. Soni P, Sharma V, Sengupta J. Cervical vertebrae anomalies-incidental findings on lateral cephalograms. Angle Orthod 2008; 78: 176–180.
4. Paxinos O, Ghanayem AJ, Zindrick MR, et al. Anterior Cervical Discectomy and Fusion With a Locked Plate and Wedged Graft Effectively Stabilizes Flexion-Distractor Stage-3 Injury in the Lower Cervical Spine. Spine 2009; 34: E9–E15.
5. Baker N. Book Review Essentials of Skeletal Radiology Second edition. Edited by Terry R. Yochum and Lindsay J. Rowe. 1526 pp. in two volumes, illustrated. Baltimore, Williams and Wilkins, 1996. \$225. 0-683-09330-4. New England Journal of Medicine 1996; 334: 1675–1676.
6. Le Minor J-M, Trost O. Bony ponticles of the atlas (C1) over the groove for the vertebral artery in humans and primates: polymorphism and evolutionary trends. Am J Phys Anthropol 2004; 125: 16–29.
7. Eriksen K. Upper Cervical Subluxation Complex: A Review of the Chiropractic and Medical Literature. Lippincott Williams & Wilkins, 2004.
8. Mitchell J. The incidence and dimensions of the retroarticular canal of the atlas vertebra. Acta Anat 1998; 163: 113–120.

9. Yochum TR, Rowe LJ. Essentials of Skeletal Radiology. Williams & Wilkins, 1996.
10. Haynes MJ, Cala LA, Melsom A, et al. Posterior ponticles and rotational stenosis of vertebral arteries. A pilot study using Doppler ultrasound velocimetry and magnetic resonance angiography. *J Manipulative Physiol Ther* 2005; 28: 323–329.
11. Wight S, Osborne N, Breen AC. Incidence of ponticulus posterior of the atlas in migraine and cervicogenic headache. *J Manipulative Physiol Ther* 1999; 22: 15–20.
12. Koutsouraki E, Avdelidi E, Michmizos D, et al. Kimmerle's Anomaly as a Possible Causative Factor of Chronic Tension-Type Headaches and Neurosensory Hearing Loss: Case Report and Literature Review. *International Journal of Neuroscience* 2010; 120: 236–239.
13. Lamberty BGH, Živanović S. The retro-articular vertebral artery ring of the atlas and its significance. *Cells Tissues Organs* 1973; 85: 113–122.
14. Young JP, Young PH, Ackermann MJ, et al. The ponticulus posticus: implications for screw insertion into the first cervical lateral mass. *J Bone Joint Surg Am* 2005; 87: 2495–2498.
15. Jayasree R, Kumar PS, Saravanan A, et al. Sequestration of toxic Pb(II) ions using ultrasonic modified agro waste: Adsorption mechanism and modelling study. *Chemosphere* 2021; 285: 131502.
16. Sivakumar A, Nalabothu P, Thanh HN, et al. A Comparison of Craniofacial Characteristics between Two Different Adult Populations with Class II Malocclusion-A Cross-Sectional Retrospective Study. *Biology* ; 10. Epub ahead of print 14 May 2021. DOI: 10.3390/biology10050438.
17. Uma Maheswari TN, Nivedhitha MS, Ramani P. Expression profile of salivary micro RNA-21 and 31 in oral potentially malignant disorders. *Braz Oral Res* 2020; 34: e002.
18. Avinash CKA, Tejasvi MLA, Maragathavalli G, et al. Impact of ERCC1 gene polymorphisms on response to cisplatin based therapy in oral squamous cell carcinoma (OSCC) patients. *Indian Journal of Pathology and Microbiology* 2020; 63: 538.
19. Chaitanya NC, Muthukrishnan A, Rao KP, et al. Oral Mucositis Severity Assessment by Supplementation of High Dose Ascorbic Acid During Chemo and/or Radiotherapy of Oro-Pharyngeal Cancers--A Pilot Project. *INDIAN JOURNAL OF PHARMACEUTICAL EDUCATION AND RESEARCH* 2018; 52: 532–539.
20. Gudipani RK, Alam MK, Patil SR, et al. Measurement of the Maximum Occlusal Bite Force and its Relation to the Caries Spectrum of First Permanent Molars in Early Permanent Dentition. *J Clin Pediatr Dent* 2020; 44: 423–428.
21. Chaturvedula BB, Muthukrishnan A, Bhuvanaraghan A, et al. Dens invaginatus: a review and orthodontic implications. *Br Dent J* 2021; 230: 345–350.
22. Patil SR, Maragathavalli G, Ramesh DNS, et al. Assessment of Maximum Bite Force in Pre-Treatment and Post Treatment Patients of Oral Submucous Fibrosis: A Prospective Clinical Study. *Journal of Hard Tissue Biology* 2021; 30: 211–216.
23. Ezhilarasan D, Apoorva VS, Ashok Vardhan N. Syzygium cumini extract induced reactive oxygen species-mediated apoptosis in human oral squamous carcinoma cells. *J Oral Pathol Med* 2019; 48: 115–121.
24. Sharma P, Mehta M, Dhanjal DS, et al. Emerging trends in the novel drug delivery approaches for the treatment of lung cancer. *Chem Biol Interact* 2019; 309: 108720.
25. Perumalsamy H, Sankarapandian K, Veerappan K, et al. In silico and in vitro analysis of coumarin derivative induced anticancer effects by undergoing intrinsic pathway mediated apoptosis in human stomach cancer. *Phytomedicine* 2018; 46: 119–130.
26. Rajeshkumar S, Menon S, Venkat Kumar S, et al. Antibacterial and antioxidant potential of biosynthesized copper nanoparticles mediated through *Cissus arnotiana* plant extract. *J Photochem Photobiol B* 2019; 197: 111531.
27. Mehta M, Dhanjal DS, Paudel KR, et al. Cellular signalling pathways mediating the pathogenesis of chronic inflammatory respiratory diseases: an update. *Inflammopharmacology* 2020; 28: 795–817.
28. Rajakumari R, Volova T, Oluwafemi OS, et al. Nano formulated proanthocyanidins as an effective wound healing component. *Mater Sci Eng C Mater Biol Appl* 2020; 106: 110056.
29. PradeepKumar AR, Shemesh H, Nivedhitha MS, et al. Diagnosis of Vertical Root Fractures by Cone-beam Computed Tomography in Root-filled Teeth with Confirmation by Direct Visualization: A Systematic Review and Meta-Analysis. *J Endod* 2021; 47: 1198–1214.
30. R H, Ramani P, Tilakaratne WM, et al. Critical appraisal of different triggering pathways for the pathobiology of pemphigus vulgaris-A review. *Oral Dis*. Epub ahead of print 21 June 2021. DOI: 10.1111/odi.13937.
31. Ezhilarasan D, Lakshmi T, Subha M, et al. The ambiguous role of sirtuins in head and neck squamous cell carcinoma. *Oral Dis*. Epub ahead of print 11 February 2021. DOI: 10.1111/odi.13798.
32. Sarode SC, Gondivkar S, Sarode GS, et al. Hybrid oral potentially malignant disorder: A neglected fact in oral submucous fibrosis. *Oral Oncol* 2021; 105390.
33. Indhulekha V, Ganapathy D, Jain AR. Knowledge and awareness on biomedical waste management among students of four dental colleges in Chennai, India. *Drug Invention Today*. 2018 Dec 1;10(12):32-41.
34. Jain AR, Dhanraj M. A clinical review of spacer design for conventional complete denture. *Biology and Medicine*. 2016;8(5):1.
35. Stubbs DM. The Arcuate Foramen. *Spine* 1992; 17: 1502–1504.
36. Bhanu PS, Sharmila Bhanu P. Incidence of Foramen of Huschke in South Andhra Population of India. *JOURNAL OF CLINICAL AND DIAGNOSTIC RESEARCH*. Epub ahead of print 2016. DOI: 10.7860/jcdr/2016/18735.8031.
37. Stubbs DM. The arcuate foramen. Variability in distribution related to race and sex. *Spine* 1992; 17: 1502–1504.
38. Sharma V, Chaudhary D, Mitra R. Prevalence of ponticulus posticus in Indian orthodontic patients. *Dentomaxillofacial Radiology* 2010; 39: 277–283.
39. Kendrick GS, Biggs NL. Incidence of the ponticulus posticus of the first cervical vertebra between ages six to seventeen. *Anat Rec* 1963; 145: 449–453.
40. Leonardi R, Santarelli A, Barbato E, et al. Atlanto-occipital ligament calcification: a novel sign in nevoid basal cell carcinoma syndrome. *Anticancer Res* 2010; 30: 4265–4267.
41. Gonçalves DAG, Camparis CM, Speciali JG, et al. Temporomandibular disorders are differentially associated with headache diagnoses: a controlled study. *Clin J Pain* 2011; 27: 611–615.
42. Plesh O, Adams SH, Gansky SA. Self-Reported Comorbid Pains in Severe Headaches or Migraines in a US National Sample. *Headache: The Journal of Head and Face Pain* 2012; 52: 946–956.