

# Case Report on Choroid Plexus Papilloma

Rajnandini Bawankar<sup>1</sup>, Ruchira Ankar<sup>2</sup>, Vaishali Tembhe<sup>2</sup>, Roshan Umate<sup>3</sup>

<sup>1</sup>Final year Basic Bsc student Smt. Radhikabai Meghe Memorial College of Nursing Sawangi Meghe Wardha.

<sup>2</sup>Associate professor, Smt. Radhikabai Meghe Memorial College of Nursing Sawangi Meghe Wardha.

<sup>3</sup>Research Scientist, Jawaharlal Nehru Medical College, Datta Meghe Institute of Medical Sciences, Sawangi, Wardha, Maharashtra.

DOI: 10.47750/pnr.2022.13.S07.152

## Abstract

Choroid Plexus Papillomas (CPPs) is also known as benign but rare central nervous system(CNS) which affect the tufts of villi that make the ventricular system choroid plexus, which is responsible for production of cerebrospinal fluid(CSF). They make up between 0.5-1% in adult and 3-4% of paediatric group. Here we are introducing 11-year-old- female who visited with her parents in paediatric outpatient unit with the complaints of headache in the frontal region and backregion. She had 4-5 episodes of vomiting in previous week, she also developed the double vision since last 2 days. The patient underwent Magnetic Resonance Imaging of the brain and found the evidence of papilla enema in both eyes. Patient went to eye department for Vitreo-retained(VR) surgery. After that client was shifted to ward for the further management where she was administered the appropriate paediatric dose of antiedema and antiepileptic medication and other supportive measures. After treatment, the patient's condition was improved than before. Symptoms such as blurred vision relieved after surgery. These tumours rarely develop in children's third ventricles, fourth ventricles or CP angle.

**Keywords:** choroid plexus Papillomas, extra-ventricular, lateral ventricle papilloma.

## INTRODUCTION

A category of benign tumours called choroid plexus Papillomas (CPPs) develops from the choroid plexus, a structure consisting of tufts of villi located within the ventricular system that secretes cerebrospinal fluid (CSF). They make up between 0.5-1% of adult and 3-4% of kids.(1)The third ventricle and the temporal horn are the two locations where CPP occurs least frequently.

Only 4% of CPPS in children under the age of five include the third ventricle, 16% involve the fourth ventricle, and nearly 80% begin in the lateral ventricle. These tumours have been classified as benign histologically, neuroectodermal in origin, and WHO grade I. Complete or gross complete removal of these tumours frequently cures the patient and virtually eliminates the risk of recurrence.(2)

These tumours present unique therapeutic concerns primarily because of their young age at presentation, high vascularity, and potential for CSF hypersecretion, among other distinctive characteristics.(3)

The most frequent locations in children and adults, respectively, are the atrium of the lateral ventricle and the fourth ventricle. The third ventricle, the cerebellopontine (CP) angle, the cerebral parenchyma, the cerebellum, and other sites are rare.(4)The atrium of lateral ventricle in children and fourth ventricle in adult are most frequent location. Only a few occurrence have been described for the third ventricle, cerebellopontine(CP)angle and cerebral parenchyma, which are all uncommon location.(5)

In the majority of instances, children arrive with elevated intracranial pressure (ICP). The location of the lesion affects other clinical characteristics. The preferred course of treatment is surgical removal, and specific surgical techniques must be used depending on the location, size, and extent of the lesion.(6)

## Case presentation:

A 11-year-old girl visited to general practitioner in her locality with the complaint of headache since 15 days, nausea, vomiting of 4 to 5 episode from 7 days. Doctor prescribed antiemetic medication and some analgesic. The pain was subsided and vomiting also reduced.

After some days she got sign of blurred vision with the symptoms of nausea, vomiting and headache hence her parents took her to paediatric outpatient department. She has under gone through the radiological investigation Magnetic resonance imaging (MRI), blood investigation and ophthalmological examination. In MRI there is irregular soft tissue density lesion showing avid enhancement noted in the posterior third ventricle region with CSF cleft appearing heterogeneously on T2W1/FLAIR hypo intense on T1W1 and showing restriction on DWI and low signal on ADC and blooming on GRE. The child has under gone through the Vitreo-retained(VR) surgery. And she was treated with Intravenous fluid, Inj. metronidazole 100mL, Inj. Pantoprazole 40mg once a day, inj. Tramadol in 100ml, Inj. Emset 4mg post operatively.

Some lesion was visible on non-contrast computed tomography (CT).The ophthalmological call was done. After investigation the doctor suggested for the operation to recover the eye. Therefore the anaesthesia was administered to the client according to the requirement, further the surgery has performed. Client ventriculo-peritoneal (VP) shunt was carried out, then a conclusive operation. In the seated position, a supracerebellar infratentorial approach was made. The tumour was vascular, soft to firm, friable, reddish, and linked to the choroidal arteries by a single pedicle. Early security of the artery feeder allowed for a successful en bloc removal. Postoperative imaging revealed no residual tumour, and the child's recovery from surgery was outstanding. After treatment, the patient's condition improves. Condition of the patient were improved after surgery hence patient was discharged with the advice to follow up after 3 weeks.

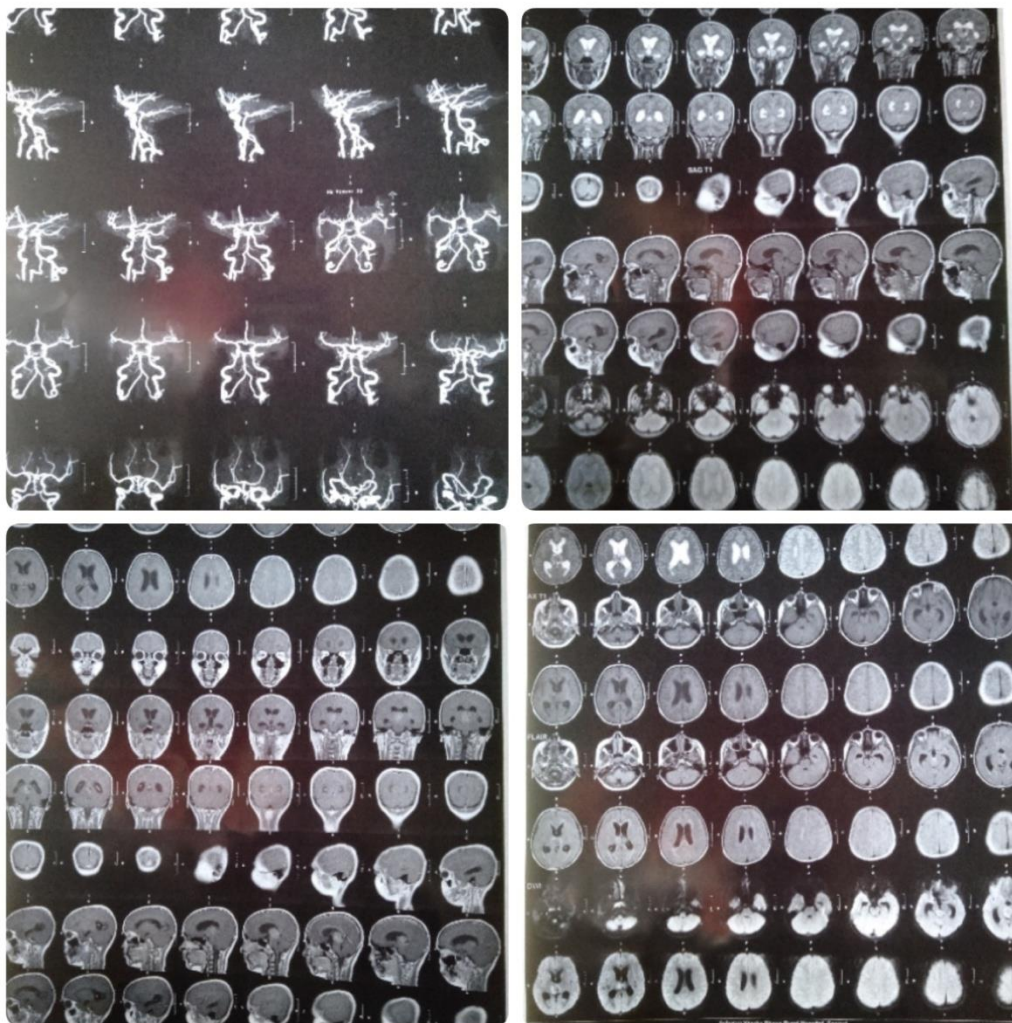
## Discussion:-

CPP are being, infrequent central nervous system tumour. Overproduction of cerebrospinal fluid (CSF), which arise from the choroid plexus boarding the ventricles and is derived from the neuroectoderm, is the defining feature of these malignancies. In most of the cases, hydrocephalus is present. The cases of this include excessive CSF production,direct tumour obstruction of CSF routes,recurrent microhaemorrhages resulting in arachnoid adhesions and increase CSF protein contraction.(7-15)

In children lateral ventricle and adults fourth ventricles,they are most frequently seen in the atrium.(8)These have been a few report of fourth ventricular CPP in children, with an incidence of 10-20%, however they are uncommon in area like the CP angle and posterior third ventricle.CPPs are well-defined soft, grayish-red cauliflower-like masses with noticeable peripheral lobulations and focal grittier patches as a result of calcification. There may be some haemorrhaging and cystic degeneration in some regions. The major blood supply for the choroid plexus tumours in the lateral ventricle is formed by the anterior choroidal artery, lateral posterior choroidal artery, and medial posterior choroidal artery. The posterior inferior cerebellar artery's choroidal branches typically supply fourth ventricle choroid plexus tumours.(16-24)

Most of the time, a vascular pedicle connects the tumours to the choroid plexus. While tumours of the third ventricle are generally linked to its roof, cancers of the lateral ventricles most frequently arise in the trigone region of the choroid plexus. The CPPs are joined to the posterior medullary velum in the fourth ventricle.(25-30)

Due to the pedicular connection, which allows for the free movement of the tumours inside the ventricles, there can occasionally be an acute constriction of the ventricles caused by gravity, leading to bobble head doll syndrome. In our case, the tumour also possessed a pedicular attachment that emerged from the temporal horn's choroid plexus, with the anterior choroidal artery serving as its vascular supply. (31-35)



## Conclusion:-

CPP are infrequent, being tumours. These tumours are rarely develop in children in third ventricle or fourth ventricle, or CP angle. The most typical manifestation is increase ICP. When there are conforming imaging finding in children, they should always be taken into account in the different diagnosis. The client came with the complaint of nausea, vomiting, headache and blurred vision. After surgical management the condition of patient was good.

## REFERENCES

1. Castro Castro J, Lista Martínez O, Cuevas Álvarez EC, Iglesias Meleiro JM, Pérez López C. Choroid plexus papilloma of the third ventricle. A case report. *Neurocirugía (Astur : Engl Ed)*. 2020 May-Jun;31(3):151-154. English, Spanish. doi: 10.1016/j.neucir.2019.06.003. Epub 2019 Aug 7. PMID: 31401052.
2. McCrea HJ, Lara-Reyna J, Perera I, Uribe R, Chotai S, Savage N, Hersh EH, Haussner T, Souweidane MM. Colloid cysts of the third ventricle in children. *J Neurosurg Pediatr*. 2021 Apr 23;27(6):700-706. doi: 10.3171/2020.10.PEDS18458. PMID: 33892476.
3. Lam KY, Lo CY, Fan ST, Luk JM. Telomerase activity in pancreatic endocrine tumours: a potential marker for malignancy. *Mol Pathol*. 2000 Jun;53(3):133-6. doi: 10.1136/mp.53.3.133. PMID: 10897332; PMCID: PMC1186919.
4. Prasad GL, Mahapatra AK. Case series of choroid plexus papilloma in children at uncommon locations and review of the literature. *Surg Neurol Int*. 2015 Sep 28;6:151. doi: 10.4103/2152-7806.166167. PMID: 26500797; PMCID: PMC4596056.
5. Sæhle T, Eide PK. Characteristics of intracranial pressure (ICP) waves and ICP in children with treatment-responsive hydrocephalus. *Acta Neurochir (Wien)*. 2015 Jun;157(6):1003-14. doi: 10.1007/s00701-015-2410-z. Epub 2015 Apr 14. PMID: 25870129.
6. Redzic ZB, Preston JE, Duncan JA, Chodobski A, Szmydynger-Chodobska J. The choroid plexus-cerebrospinal fluid system: from development to aging.

- Curr Top Dev Biol. 2005;71:1-52. doi: 10.1016/S0070-2153(05)71001-2. PMID: 16344101.
7. Scotti G, Musgrave MA, Fitz CR, Harwood-Nash DC. The isolated fourth ventricle in children: CT and clinical review of 16 cases. *AJR Am J Roentgenol*. 1980 Dec;135(6):1233-8. doi: 10.2214/ajr.135.6.1233. PMID: 6779530.
  8. Zagórska-Swiezy K, Litwin JA, Gorczyca J, Pityński K, Miodoński AJ. Arterial supply and venous drainage of the choroid plexus of the human lateral ventricle in the prenatal period as revealed by vascular corrosion casts and SEM. *Folia Morphol (Warsz)*. 2008 Aug;67(3):209-13. PMID: 18828104.
  9. Gomez DG, Potts DG. The lateral, third, and fourth ventricle choroid plexus of the dog: a structural and ultrastructural study. *Ann Neurol*. 1981 Oct;10(4):333-40. doi: 10.1002/ana.410100404. PMID: 7316486
  10. Chen T, Mastorakos GM, Swanson KI, Eschbacher JM, Smith KA. Temporal Horn Choroid Plexus Papilloma Presenting with Seizures in Adulthood: Clinical Case Report and Review of the Literature. *World Neurosurg*. 2019 Dec;132:403-407. doi: 10.1016/j.wneu.2019.08.201. Epub 2019 Sep 5. PMID: 31493601.
  11. Malani, Shailesh, and Bhushan Madke. "Dermoscopy of Epidermization of Lip Indicating Focal Compact Sebaceous Metaplasia." *Dermatology Practical & Conceptual*, July 8, 2021, 2021026. <https://doi.org/10.5826/dpc.1103a26>.
  12. Maldhure, Swati, Vaibhav Sonwani, Ranjeet Ambad, and Dhruva Hari Chandi. "Awareness about Nanotechnology among Upcoming Clinicians in Vidarbha, Maharashtra." *Journal of Pharmaceutical Research International*, July 12, 2021, 126–31. <https://doi.org/10.9734/jpri/2021/v33i36B31958>.
  13. Malhotra, Geetika, D. D. Wagh, and Meenakshi Yeola. "Study of Clinical Profile of Carcinoma Breast and Prognostic Significance of Serum Lactate Dehydrogenase as Tumor Marker in Carcinoma Breast." *Journal of Pharmaceutical Research International*, July 30, 2021, 162–67. <https://doi.org/10.9734/jpri/2021/v33i39A32155>.
  14. Mallick, Rizwana, Sweta Kale Pisulkar, and Srinivas Gosla Reddy. "Assessment of Outcomes of Immediately Loaded Dental Implants in Orofacial Cleft Patients: Protocol for a Single-Arm Clinical Trial." *JMIR Research Protocols* 10, no. 5 (May 5, 2021): e25244. <https://doi.org/10.2196/25244>.
  15. Mamidipalli, SaiSpoothry, SanghaMitra Godi, Supriya Mahant, and PuneetKumar Soni. "Type-II Sturge-Weber Syndrome and Comorbidity with Bipolar Disorder." *Annals of Indian Psychiatry* 5, no. 1 (2021): 83. [https://doi.org/10.4103/aip.aip\\_50\\_20](https://doi.org/10.4103/aip.aip_50_20).
  16. Mandal, Sucharita, Sangha Mitra Godi, and Mamidipalli Spoothry. "Sexual Dysfunction and Satisfaction in Males With Alcohol Dependence: A Clinic-Based Study From Central India." *Cureus*, August 27, 2021. <https://doi.org/10.7759/cureus.17492>.
  17. Manekk, Roshani S., and Aditya Mehta. "Recurrence of Primary Pulmonary Hydatidosis in the Left Lung with No Hepatic Involvement." *Journal of Evolution of Medical and Dental Sciences* 10, no. 10 (March 8, 2021): 746–48. <https://doi.org/10.14260/jemds/2021/160>.
  18. Mankar, Swapnali S., Muh. Younas, Awadhut Pimpale, and Devyani Awari. "Pharmacognostic and Pharmacological Study of *Helicteres Isora*. Linn. - A Review." *Journal of Pharmaceutical Research International*, November 11, 2021, 208–14. <https://doi.org/10.9734/jpri/2021/v33i49A33322>.
  19. Mankar, Swapnali Suresh, Muhammad Younas, Vaishavi Kalode, Pranita Jirvankar, Prasanna Phutane, Shital Chandewar, Ashwini Armarkar, and Anil Pethe. "Selective SGLT2 Inhibitor's Estimation and Validation from Galenic Form by RP-HPLC Method." *Journal of Pharmaceutical Research International*, December 14, 2021, 57–68. <https://doi.org/10.9734/jpri/2021/v33i57B34029>.
  20. Mastud, Kiran, Y. R. Lamture, and Meenakshi Yeola(Pate). "A Comparative Study between Conventional Sutures, Staples and Adhesive Glue for Clean Elective Surgical Skin Closure." *Journal of Pharmaceutical Research International*, June 9, 2021, 90–97. <https://doi.org/10.9734/jpri/2021/v33i31A31667>.
  21. Mathurkar, Swapneel, Sachin Daigavane, Madhumita Prasad, and Kervi Mehta. "Correlation of Chronic Smoking with Meibomian Gland Dysfunction – A Study at Wardha, Maharashtra, India." *Journal of Evolution of Medical and Dental Sciences* 10, no. 19 (May 10, 2021): 1382–86. <https://doi.org/10.14260/jemds/2021/292>.
  22. Maurya, Archana, B. Lakhakar, Bibin Kurian, and Switi Beseekar. "Effectiveness of Kangaroo Mother Care in Weight Gain among Newborn Babies in AVBRH Hospitals of Wardha." *Journal of Pharmaceutical Research International*, October 23, 2021, 532–37. <https://doi.org/10.9734/jpri/2021/v33i46B32972>.
  23. Maurya, Archana, Vishakha Meshram, Khushboo Mungle, Viwek Nade, and Payal Nanotkar. "To Assess Awareness and Stress Level Regarding COVID-19 Pandemic among Banker." *Journal of Pharmaceutical Research International*, October 23, 2021, 593–99. <https://doi.org/10.9734/jpri/2021/v33i46B32981>.
  24. Maurya, Archana, Hina Y. Rodge, Bibin Kurian, and Sagar Alwadkar. "Total Anomalous of Pulmonary Venous Connection- A Case Report." *Journal of Pharmaceutical Research International*, July 31, 2021, 226–30. <https://doi.org/10.9734/jpri/2021/v33i39A32164>.
  25. Maurya, Archana T, Pradnya P Wankhede, Pritesh D Warghane, Ankita A Yelane, Chaitali P Yengade, and Nikita D Zade. "Effectiveness of Self-Instructional Modules on Knowledge Regarding Side-Effects of Self-Medication among Adolescents." *JOURNAL OF CLINICAL AND DIAGNOSTIC RESEARCH*, 2021. <https://doi.org/10.7860/JCDR/2021/44855.15027>.
  26. Maurya, Archana, Karishma Wanjari, David Wanmali, Atul Warutkar, Snehal Wasekar, and Bhagyashri Watmode. "Effectiveness of Planned Teaching on Knowledge Regarding Cadverdonation among Adults in Rural Area." *Journal of Pharmaceutical Research International*, October 2, 2021, 6–11. <https://doi.org/10.9734/jpri/2021/v33i45B32771>.
  27. Mendhe, Deeplata, Divyani Kanholkar, Ranjana Sharma, Kavita Gomase, and Mayur Wanjari. "A 1 Year Child with Hydrocephalus: A Case Report." *Journal of Pharmaceutical Research International*, October 29, 2021, 826–30. <https://doi.org/10.9734/jpri/2021/v33i47A33078>.
  28. Mendhe, Deeplata, Pratibha Wankhede, Mayur Wanjari, and Sagar Alwadkar. "Mucormycotic Osteomyelitis of Maxilla Post-COVID Patient: A Case Report." *Pan African Medical Journal* 39 (2021). <https://doi.org/10.11604/pamj.2021.39.275.30480>.
  29. Meshram, Ayushi, Rakesh Kumar Jha, and Parikshit Muley. "A Review Article on the Relation between Anxiety and Depression." *Journal of Pharmaceutical Research International*, July 28, 2021, 31–34. <https://doi.org/10.9734/jpri/2021/v33i39A32137>.
  30. Meshram, Dharti, Jaya Gawai, and Pooja Kasturkar. "A Case Report on Alzheimers Dementia." *Journal of Pharmaceutical Research International*, October 5, 2021, 147–52. <https://doi.org/10.9734/jpri/2021/v33i45B32791>.
  31. Meshram, Dharti, Jaya Gawai, and Pooja Kasturkar. "A Clinici Case Report on Black Dog (Depression)." *Journal of Pharmaceutical Research International*, July 30, 2021, 181–85. <https://doi.org/10.9734/jpri/2021/v33i39A32158>.
  32. Meshram, Dharti, and Pooja Kasturkar. "Assessment of Common Mental Health Problems among General Population." *Journal of Pharmaceutical Research International*, July 13, 2021, 210–17. <https://doi.org/10.9734/jpri/2021/v33i36B31970>.
  33. Meshram, Dharti, Sonali Wavare, Trupti Uke, and Shabnam Sayyad. "A Case Report on Schizophrenia with Autoimmune Encephalitis." *Journal of Pharmaceutical Research International*, December 14, 2021, 20–24. <https://doi.org/10.9734/jpri/2021/v33i58A34084>.
  34. Meshram, Khushbu, Vaishali Tembhare, Archana Taksande, Savita Pohekar, Pooja Kasturkar, Darshanakumari Wankhede, and Prerana Sakharwade. "Preventive Recommendations to Reduce the Impact of Poor Ergonomics on Children during Online Learning." *Journal of Pharmaceutical Research International*, December 14, 2021, 247–52. <https://doi.org/10.9734/jpri/2021/v33i57B34053>.