

Ameliorative Effect of Dandelion Leaves Extract Against Liver Injury Induced by Schistosomiasis in Mice

Nahed S. Amer, Amal I. El-Refaiy

Biological and Environmental Sciences Department, Faculty of Home Economics, Al-Azhar University, Tanta 31732, Egypt.

Email: elrefaiyamal@gmail.com

Abstract

The present study is planned to investigate the effect of dandelion leaves water extract (DWE) on Schistosomiasis. Thirty-five adult male albino mice weighing 20-25 g were used and divided into two main groups, the main first group served as a normal control group without infection (n=7); the second main group was infected with *S. mansoni* (n=28). After 45 days post-infection the second main group was divided into four subgroups; the first subgroup infected with *S. mansoni* without treatment (IC) and served as positive control group, the second subgroup infected with *S. mansoni* then treated by praziquantel (PZQ), the third subgroup infected with *S. mansoni* then treated by DWE, and the fourth subgroup infected with *S. mansoni* then treated by DWE in combination with PZQ.

The results indicated that administration of combined DWE+PZQ is more effective in all parameters than PZQ or DWE and exhibited highly significantly reduced parasitological parameters, the number and diameter of hepatic granulomas, and histopathological changes in the liver as compared to the untreated infected group. The results also showed that the administration of DWE+PZQ remarkably reduced AST and ALT activities and increment of serum albumin. These amelioration effects were observed in DWE+PZQ treated group, then PZQ-treated group, followed by the group treated with DWE only. This study concluded that dandelion leaves water extract can be added as a potential treatment against schistosomiasis when combined with the anti-schistosomal drug praziquantel.

Keywords: Dandelion, Polyphenols, Liver, Schistosomiasis, Mice.

DOI: 10.47750/pnr.2022.13.S08.322

INTRODUCTION

Schistosoma infection is the third most destructive tropical disorder in the world and resulted in significant morbidity and mortality on many continents (Rollinson et al., 2013). Schistosomiasis was considered a tropical disease-causing histological deformation in different organs (Abu Almaaty et al., 2021). It is a parasitic disease caused by bloodworms that infect multiple organs, including the liver, intestine, bladder, and urethra. These diseases may be eliminated with gene therapy, vaccines, and Praziquantel (Nelwan, 2019). Microscopic histopathological examination is still one of the most common methods of scoring used by investigators (Ibrahim et al., 2018; Miao et al., 2010).

The liver is considered one of the vital organs of the human body, it has an important role in the regulation of physiological processes and many vital functions. Due to its unique anatomic location and function, the liver is exposed to many forms of disorders. Liver pathological changes such as fatty liver, increase in reactive oxygen species (ROS) or oxidative stress, hepatitis, necrosis of liver cells, cholestasis, steatosis, granuloma and vascular

lesions, fibrosis, increase in the inflammatory markers, hepatocellular carcinoma, cirrhosis which further produce portal hypertension and organ failure (Singh et al., 2011).

Schistosomiasis caused deformation of degradation of hepatic cords, necrosis of hepatocytes, and degeneration of hepatocytes. These changes could be due to granuloma formation, and hypertrophy of Kupffer cells. Marked increased lipid vacuoles and depletion of carbohydrates were also detected (Mostafa et al., 2011; Mahmoud et al., 2016).

Praziquantel (PZQ) is considered the only drug appropriate to treat schistosomiasis. Resistance of PZQ is a potential threat to the control of the disease although PZQ is effective against all species of schistosomes (Basha and Mamo, 2021). The long-term worldwide use of praziquantel (PZQ), the only drug of choice, resulted in the discovery of PZQ-tolerant schistosomes which had induced concern over the development of drug-resistant Schistosoma strains (Danso-Appiah and De Vlas, 2002). Moreover, some cases recorded resistance and tolerance from parasites against this therapy. Because of these defects of PZQ, the need to find a new therapeutic

approach, especially from natural plant derivatives, has been raised (Abdulla et al, 2007; Mahmoud et al, 2014).

There are several derived agents from plants have shown promising hepatoprotective properties as; resveratrol, curcumin, silymarin, silibinin, berberine, and dandelion (Ezhilarasan et al., 2012; Ezhilarasan et al., 2014). Dandelion (*Taraxacum officinalis*) is a perennial plant belonging to the Asteraceae family. Due to the content of biologically active ingredients in the leaves, flowers, and roots, its traditional use has been documented in many countries (Hu, 2018).

T. officinale is a traditional herbal medicine used for the treatment of liver disorders, jaundice, and gallbladder (You et al., 2010; Ahmed et al., 2013). The folk medicines of Russia, India, and China have recognized the *T. officinale* effect as a liver tonic. Roots and herbs have been reported to use for the treatment of various ailments, including liver and gallbladder disorders (Gulfraz et al., 2014). Traditional Chinese medicine combines *T. officinale* with other herbs to treat liver disorders (Modaresi and Resalatpour, 2012).

Schutz et al. (2006) stated that *T. officinale* has been used in ethnopharmacology as a traditional therapeutic drug due to its biological and pharmacological properties, such as its hepatoprotective and hypoglycemic activities. Dandelion contains compounds with antioxidant potential (polyphenols, vitamins, and terpenes), natural antioxidants protect organisms against oxidative stress, which is an important factor in the aging process and in the pathogenesis of neoplastic, cardiovascular, neurodegenerative, and some other diseases (Nowak et al., 2019).

Dandelion is rich in potential bioactive components such as lactones, chlorogenic acid, taraxerol, taraxasterol, and chicory acid. These components are non-toxic and can be used for their potent anti-oxidative, anti-inflammatory, and anti-rheumatic properties. (Arpadjan et al., 2008; Yarnell and Abascal, 2009). Other components have not been fully characterized and therefore their activities remain unknown (Schutz et al., 2006). Biologically active compounds have been found in various parts of this plant. The leaves contain substances belonging to the group of flavonoids, phenolic acids, coumarins, and vitamins, especially vitamin A (Lis and Grabek-Lejko, 2016). High concentrations of minerals, vitamins, fiber, and essential fatty acids are found in the leaves of *T. officinalis* (Escudero et al., 2003). Also, Schütz et al. (2006) stated that dandelion leaves extract has shown stronger hydrogen peroxide scavenging activity compared with the root extract because of its high polyphenol content.

dandelion has garnered attention for its antioxidant and anti-inflammatory effects and its possible beneficial

effects against the development of obesity, cancer, and numerous cardiovascular risk factors (Jeon et al., 2017). The aqueous extract of dandelion has been recorded as having strong anti-tumor promotion activities in the two-stage carcinogenesis of mouse skin tumors induced by an initiator and a promoter. In addition, the extract also has anti-inflammatory, antinociceptive activities and antiangiogenic that is, able to minimize the production of nitric oxide and cyclooxygenase 2 and decrease the rate of ROS (reactive oxygen species) in cells activated macrophages (Takasaki et al., 1999).

Nowadays, dandelion is used as an available dietary supplement as well as in pharmaceutical preparations due to its choleric, diuretic, growth-promoting, antirheumatic, anticancer, antimicrobial, and anti-inflammatory properties (Park et al., 2010; Lis et al., 2018). There are limited scientific studies investigating the anti-parasitic activity of dandelion leaves extract, for this, the present study aimed to demonstrate the antiparasitic and hepatoprotective properties of dandelion leaves extract on mice infected with *S. mansoni* and compared to PZQ.

Materials and Methods

Plant Material.

The leaves of *T. officinale* (dandelion) were collected in February 2022 from City of El-Mahalla El-Kubra, Egypt, and authenticated by the corresponding author.

Preparation of Extract:

The sample of *T. officinale* was dried at $25 \pm 5^\circ\text{C}$ then homogenized to a fine powder. 100 g of powdered dandelion put in distilled water at 100°C (1: 20, w/v) for 10 min. then, the water extract was filtered through Whatman No. 1 filter paper and evaporated under a vacuum at 40°C (Zanatta et al., 2021). dandelion water extract (DWE) was given in a dose of 500 mg/ kg/day from the day 45 post infection for two weeks.

Phytochemical Analysis:

Identification and Quantification of polyphenolic Compounds carried out in Food Safety and Quality Control Lab (FSQC), Faculty of Agriculture, Cairo University by methods of Agilent Application Note, publication number 5991-3801 EN, 2014. Agilent 1260 infinity HPLC series (Agilent, USA) was used, equipped with Quaternary pump, the column used: aKinetex® 1.7µmEVO C1850mmx2.1mm. (Phenomenex, USA), operated at 30°C . The separation is achieved using a

ternary linear elution gradient with (A) HPLC grade water 0.1% H₃PO₄ (v/v), (B) acetonitrile 0.1% H₃PO₄ (v/v), (C) methanol. flow rate 0.2ml/min. The injected volume was 20 µL. Detection: variable wavelength detector (VWD) set at 280nm.

Drug:

Praziquantel (PZQ) was obtained from Egyptian International Pharmaceutical Industries Company (E.I.P.I.C.O.) and was suspended in 2% Cremophore (EL, Sigma Chemical Company, St. Louis, MO, USA) and given orally after 45 days post infection at a dose of 500 mg/kg for two consecutive days (El-Lakkany et al., 2012).

Experimental animals:

The experiments were carried out on Thirty-five adult male Albino mice weighing 20–25 g, bred in Schistosoma Biological Supply Center at Theodor Bilharz Research Institute (TBRI). All experiments were performed following “Principles of laboratory animal care”. The mice were acclimatized to conditions in the laboratory 26 - 28 C°, 12h light/dark cycle) for 7 days prior to the beginning of treatment, during which they received standard diet and tap water ad libitum (Bishayee et al., 1995).

Infection of mice:

The animals of experiment were conducted at the TBRI animal unit. Twenty-eight mice were infected by subcutaneous injection of 80±10 cercariae per mouse of an Egyptian strain of *S. mansoni* (Peters and Warren, 1969).

Experimental Design:

Animals were randomly divided into two main groups; the First group served as normal control group without infection or treatment (7 mice). Second main group (28 mice) infected by subcutaneous injection of 80±10 cercariae per mouse and after 45 days post infection divided into four subgroups (n=7). The first infected with

S. mansoni without treatment and served as positive control (IC), the second infected with *S. mansoni* then treated by PZQ, the third infected with *S. mansoni* then treated by DWE, and the fourth infected with *S. mansoni* then treated by DWE in combination with PZQ.

Sample collection:

At the end of experiment, all animals were euthanized by decapitation. Peripheral blood was collected from each animal, and serum was separated by centrifugation at 3000 rpm for 10 min. and kept at -20 °C until used for biochemical studies. Livers were immediately removed from all mice, and each one was divided into two parts. The first part of liver was fixed in 10% formalin and used for histopathological study and measuring granuloma diameter. The second part was used for the determination of ova count and developmental stages of schistosome eggs (Pellegrino et al., 1962). Segments of the intestine were also removed for ova counting and Oogram studies.

Biochemical Serum Analysis:

Serum samples were collected in aliquots for determination of serum alanine transaminase (ALT), serum aspartate transaminase (AST) (Henry et al., 1974), and serum albumin concentration (Pinnell and Northam, 1978).

Worm burden:

Perfusion of liver, portal and mesenteric veins with cold saline was performed to determine worm burden and percentage of worm reduction. Male, female and coupled worms were counted (Duvall and DeWitt, 1967). The worm burden was determined as the percentage of maturation of cercariae into adult worms (Freire et al., 2003).

The percentage reduction of worm burden in all infected groups was calculated according to the following equation:

$$\text{Worm burden reduction}\% = \frac{\text{Mean of worms from control group} - \text{mean of worms from treated group}}{\text{Mean of worms from control group}} \times 100$$

Egg Developmental Stages (Oogram Pattern):

Developmental stages of eggs were determined; the mature stage contains a fully developed miracidium; the immature stage contains abnormal miracidia. In addition, the dead ova were counted and recorded. The number of

eggs/grams of small intestine tissue of infected mice was detected according to (Pellegrino and Goncalves, 1965).

Tissue egg load:

Samples of intestine (ileum) and liver were collected from each mouse and digested in 5% KOH at 37 °C for 16 h. Ova were counted under the light microscope at x 40. calculation the number of eggs/gram tissues in liver and intestine was performed according to (Herbert et al., 2010).

Histological studies:

The fixed specimens of liver were washed and transferred to 70% ethanol, dehydrated in ascending ethanol, cleared in xylene, embedded in paraffin wax, and sectioned at 5µ thickness. The sections were then stained with Harries Hematoxylin and Eosin (Delafield, 1984), and Masson's trichrome to demonstrate the collagenous fibers (Humason, 1972). Paraffin sections were used for the count of granuloma numbers and measuring of their diameter and histopathological studies.

Number and diameter of Granuloma

Granulomas were counted and their diameter was digitally measured using a multi-head microscope. Only granuloma with a single ovum was measured. (Jacobs et al., 1997).

Statistical Analysis

Data were analyzed using Statistical Program for Social Science (SPSS) version 20.0 Quantitative data were expressed as mean± standard deviation (SD). Tests were one-way analysis of variance (ANOVA) when comparing between more than two means. Post Hoc test was used for multiple comparisons between different variables. Low Significant at p value < 0.05 , moderate significant at p value < 0.01, and high significant at p value < 0.001.

Results:

Phytochemical Analysis

The aqueous extract of dandelion (*T. officinale*) used in the present study was analyzed by FSQC-HPLC1260 (Agilent Technologies, USA) and carried out to obtain information about the qualitative and quantitative polyphenol contents in the samples of plant extract. Identification of these polyphenolic compounds in leaves extract sample was checked according to retention time obtained from standard run at identical conditions. The compounds identified are gallic acid, caffeic acid, chlorogenic acid, syringic acid, ferulic, rutin, myricetin, quercetin, rosmarinic acid, apigenin and kaempferol. Rosemarinic acid was the major polyphenolic compound (16829.14243mg/kg at 13.537min), while the minor polyphenolic compound is rutin (49.25192mg/kg at 9.824min) (Fig.1, Table 1).

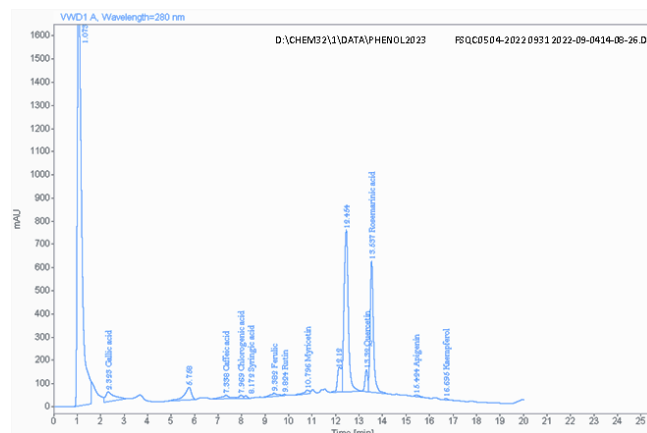


Fig. 1: Chromatogram obtained by HPLC analysis of a *Taraxacum officinale* leaves extract at 280 nm. The compounds identified are Gallic acid, Caffeic acid, Chlorogenic acid, Syringic acid, Ferulic, Rutin, Myricetin, Quercetin, Rosemarinic acid, Apigenin and Kaempferol.

Table 1: Composition of polyphenolic compounds in *Taraxacum officinale* leaves extract by HPL

Compound	RT [min]	Area	Amount [mg/kg]
Gallic acid	2.323	1109.0220	998.65228
Caffeic acid	7.338	357.2402	349.16572
Chlorogenic acid	7.969	166.3202	293.85249
Syringic acid	8.172	91.7083	64.39582
Ferulic	9.382	276.5160	438.85575
Rutin	9.824	41.8615	49.25192
Myricetin	10.796	256.7643	484.19328
Quercetin	13.320	756.7056	1334.32296
Rosemarinic acid	13.537	5500.1099	16829.14243
Apigenin	15.424	131.2235	175.68643
Kaempferol	16.695	73.7716	91.72130
Max Conc.			16829.14243

Parasitological parameters:

The data represented in Table 2 illustrated that the mean total worm burden showed a highly significant ($p < 0.001$)

reduction in each of the DWE+ PZQ treated group and by PZQ treated group followed finally dandelion treated group (DWE) with percent (100%, 96.84%, and 68.20%, respectively) when compared to the infected untreated group (IC). However, there was a significant difference in mean worm burden reduction of (PZQ + DWE group) as compared to (DWE group).

Table 2. The effect of PZQ, DWE, and its combination on mean worm burden in mice infected with *S. mansoni*

Mean worm burden +SD (liver and Porto-mesenteric)																	
	Male				Female				Couples				Total				% Total worm burden reduction
F test	35.200				1.000				188.559				340.288				
P value	0.001***				0.410				0.001***				0.001***				
	Mean ± SD	P1	P2	P3	Mean ± SD	P1	P2	P3	Mean ± SD	P1	P2	P3	Mean ± SD	P1	P2	P3	
IC	3.14 ± 0.90	-	-	-	0.14 ± 0.38	-	-	-	7.00 ± 1.15	-	-	-	17.14 ± 2.04	-	-	-	-
PZQ	0.29 ± 0.49	0.001***	-	-	0.00 ± 0.00	0.503	-	-	0.00 ± 0.00	0.001***	-	-	0.29 ± 0.49	0.001***	-	-	96.84
DWE	0.57 ± 0.79	0.001***	0.841	-	0.00 ± 0.00	0.503	1.0	-	2.57 ± 0.53	0.001***	0.001***	-	5.71 ± 0.95	0.001***	0.001***	-	68.20
PZQ + DWE	0.00 ± 0.00	0.001***	0.841	0.368	0.00 ± 0.00	0.503	1.0	1.0	0.00 ± 0.00	0.001***	1.0	0.001***	0.00 ± 0.00	0.001***	0.966	0.001***	100

Data represented by mean ± SE (n = 7)

P1: Comparison with IC, P2: Comparison with PZQ, P3: Comparison with DWF.

* Significant p value < 0.05 , ** Significant p value < 0.01 , *** Significant p value < 0.001

The data reported in Table 3 revealed that groups treated with combination (DWE + PZQ), PZQ, or DWE-only showed highly significant ($p < 0.001$) reduction in the egg count means either in the liver or in the intestine as compared to infected untreated group (IC). The percent of total ova reduction in groups treated with the combination

of DWE + PZQ, PZQ, and DWE was (94.39%, 91.90%, and 44.32% respectively) as compared to group treated with DWE-only with percent in liver and in intestine. There was a highly significant difference in egg count means of (PZQ + DWE group) as compared to group treated with DWE only.

Table 3. The effect of PZQ, DWE, and its combination on hepatic and intestinal ova count in mice infected with *S. mansoni*

% Egg developmental stages ± SD												
Ova count	Immature ova				Mature ova				Dead ova			
F test	392.398				197.650				744.610			
P value	0.001***				0.001***				0.001***			
	Mean ± SD	P1	P2	P3	Mean ± SD	P1	P2	P3	Mean ± SD	P1	P2	P3
IC	50.43 ± 1.27	-	-	-	44.71 ± 1.80	-	-	-	5.02 ± 0.79	-	-	-
PZQ	0.00 ± 0.00	0.001**	-	-	6.71 ± 1.80	0.001**	-	-	93.29 ± 1.80	0.001**	-	-
DWE	43.14 ± 2.12	0.001**	0.001**	-	41.29 ± 1.98	0.001**	0.001**	-	15.57 ± 1.27	0.001**	0.001**	-
PZQ +DWE	0.00 ± 0.00	0.001**	1.0	0.001**	3.29 ± 1.80	0.001**	0.002*	0.001**	96.71 ± 1.80	0.001**	0.027*	0.001**

Data represented by mean ± SE (n = 7)

P1: Comparison with IC, P2: Comparison with PZQ, P3: Comparison with DWF.

* Significant p value < 0.05 , ** Significant p value < 0.01 , *** Significant p value < 0.001

The data represented in Table 4 showed that groups treated with a combination of (DWE + PZQ), PZQ, or DWE alone showed highly a significant (p < 0.001) decrease in immature and mature ova when compared with IC. On the other hand, all treated groups showed a

highly significant increase in dead egg count when compared with IC. Group treated with (DWE + PZQ) was more effective on mature and dead ova when compared with group treated with PZQ.

Table 4. The effect of PZQ, DWE and its combination on oogram pattern (Immature, mature and dead ova) in mice infected with *S. mansoni*

Ova count	Mean egg count/gram Liver				Mean egg count/gram Intestine				Total ova/ mice				% Total ova reduction
F test	269.380				134.990				199.812				
P value	0.001***				0.001***				0.001***				
	Mean ± SD	P1	P2	P3	Mean ± SD	P1	P2	P3	Mean ± SD	P1	P2	P3	
IC	6139 ± 569.04	-	-	-	7288.9 ± 1225.4	-	-	-	13428 ± 1757.4	-	-	-	-
PZQ	585.14 ± 230.36	0.001**	-	-	501.71 ± 112.25	0.001**	-	-	1086.9 ± 238.42	0.001**	-	-	91.90
DWE	3446.6 ± 632.61	0.001**	0.001**	-	4028.4 ± 841.81	0.001**	0.001**	-	7475 ± 1385.6	0.001**	0.001**	-	44.32
PZQ +DWE	313.86 ± 58.191	0.001**	0.664	0.001**	439.57 ± 75.476	0.001**	0.999	0.001**	753.43 ± 92.267	0.001**	0.945	0.001**	94.39

Data represented by mean ± SE (n = 7)

P1: Comparison with IC, P2: Comparison with PZQ, P3: Comparison with DWF.

* Significant p value < 0.05 , ** Significant p value < 0.01 , *** Significant p value < 0.001

Biochemical analysis:

The levels of albumin were significantly reduced (P < 0.001) in *S. mansoni* infected mice (3.08 ± 0.11) compared with normal values

recorded in uninfected control group (4.40 ± 0.15).

Treatment of infected mice with combination of DWE+PZQ, PZQ, or DWE, showed raising in the concentrations of serum albumin, being (3.61 ± 0.13 , 3.54 ± 0.10 and 3.36 ± 0.16) respectively when compared with untreated infected group.

Highly significant increase in serum AST and ALT levels (131.57 ± 2.64 , 160.29 ± 2.56 U/L) respectively were observed in untreated infected group when compared with uninfected control group (53.16 ± 1.43 , 63.64 ± 3.01). Treatment of infected mice with a combination of DWE+PZQ, PZQ, or DWE, showed highly significant reduction in the serum enzymes AST and ALT levels as compared to untreated infected group (Table 4 and figure 2). Groups treated with DWE+PZQ and PZQ give more effective than group treated with DWE.

Table 5. The effect of PZQ, DWE, and its combination on albumin, AST enzyme, and ALT enzyme in mice sera infected by *S. mansoni*.

	Albumin g/dl					AST (U/L)					ALT (U/L)				
F test	95.469					2625.494					1082.300				
P value	0.001***					0.001***					0.001***				
	Mean ± SD	P1	P2	P3	P4	Mean ± SD	P1	P2	P3	P4	Mean ± SD	P1	P2	P3	P4
Normal	4.40 ± 0.15	-	-	-	-	53.16 ± 1.43	-	-	-	-	63.64 ± 3.01	-	-	-	-
IC	3.08 ± 0.11	0.001***	-	-	-	131.57 ± 2.64	0.001**	-	-	-	160.29 ± 2.56	0.001***	-	-	-
PZQ	3.54 ± 0.10	0.001***	0.001***	-	-	51.14 ± 2.27	0.240	0.001***	-	-	63.71 ± 0.76	1.0	0.001***	-	-
DWE	3.36 ± 0.16	0.001***	0.004**	0.095	-	90.33 ± 0.70	0.001**	0.001***	0.001***	-	93.57 ± 6.00	0.001***	0.001***	0.001**	-
PZQ+DWE	3.61 ± 0.13	0.001***	0.001***	0.852	0.009**	57.71 ± 1.11	0.001**	0.001***	0.001***	0.001***	65.43 ± 1.99	0.854	0.001***	0.872	0.001***

Data represented by mean ± SE (n = 7)

P1: Comparison with Normal, P2: Comparison with IC, P3: Comparison with PZQ, P4: Comparison with DWE.

* Significant p value < 0.05 , ** Significant p value < 0.01 , *** Significant p value < 0.001

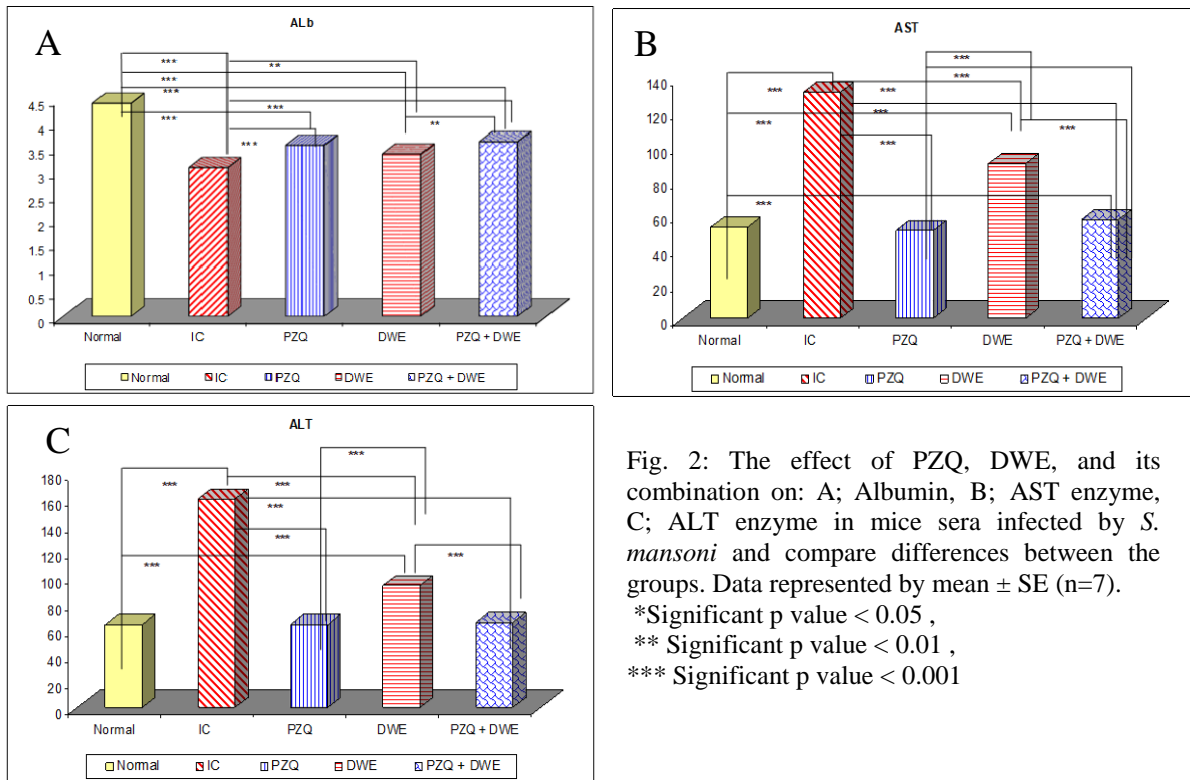


Fig. 2: The effect of PZQ, DWE, and its combination on: A; Albumin, B; AST enzyme, C; ALT enzyme in mice sera infected by *S. mansoni* and compare differences between the groups. Data represented by mean \pm SE (n=7).
 *Significant p value < 0.05 ,
 ** Significant p value < 0.01 ,
 *** Significant p value < 0.001

Histological study:

Diameter and number of Granuloma:

A significant reduction in the diameter and number of Granuloma showed in groups treated with a combination of (DWE + PZQ), PZQ, or DWE compared with the untreated infected group (IC). The least Granuloma diameter and number (151.57 ± 25.22 , 4.17 ± 1.12) respectively was detected in mice treated with DWE+PZQ, followed by PZQ treated mice

(168.24 ± 21.20 , 5.64 ± 2.15) and was (298.49 ± 24.16 , 9.98 ± 1.31) in mice treated with DWE only as compared to their corresponding untreated infected group (349.32 ± 22.17 , 14.9 ± 3.11). Thus, the greatest reduction in the mean hepatic granuloma diameter and number was observed in the DWE+PZQ treated group (56.61%, 72.01%), respectively, followed by PZQ group (51.84%, 62.15%) and finally in DWE group (14.55%, 33.02%). DWE+PZQ was the most effective, followed by PZQ-treated mice, then mice treated with DWE only (Table 6). Also, types of granuloma and state of *S. mansoni* eggs were detected as shown.

Table 6: Showing some Parameters of granuloma area in liver of *S. mansoni* infected mice and treated groups.

F test	Granuloma diameter				% Reduction	No. of granuloma				% reduction in successive power fields (10x10) mean \pm SE	Types of Granuloma			% State of <i>S. mansoni</i> eggs	
	250.631					147.632					Fibrous %	Fibrocellular %	Cellular %	Degenerated	Intact
	P-value					0.410									
	Mean \pm SD	P1	P2	P3		Mean \pm SD	P1	P2	P3						
IC	349.32 \pm 22.17	-	-	-	-	14.9 \pm 3.11	-	-	-		0	23	77	5	95
PZQ	168.24 \pm 21.20	0.001 ***	-	-	51.84	5.64 \pm 2.15	0.001 ***	-	-	62.15	0	45	55	46	54
DWE	298.49 \pm 24.16	0.001 ***	0.001 ***	-	14.55	9.98 \pm 1.31	0.001 ***	0.001 ***	-	33.02	0	35	65	12	88
PZQ + DWE	151.57 \pm 25.22	0.001 ***	0.217	0.001 ***	56.61	4.17 \pm 1.12	0.001 ***	0.106	0.001 ***	72.01	0	48	52	65	35

Data represented by mean \pm SE (n = 7)

P1: Comparison with Normal, P2: Comparison with IC, P3: Comparison with PZQ, P4: Comparison with DWF.

* Significant p value < 0.05, ** Significant p value < 0.01, *** Significant p value < 0.001

Histopathological observations:

Histopathological observations of hepatic tissues of untreated infected group (IC) showed chronic granulomatous inflammation marked by numerous cellular granulomas and inflammatory cells rich in eosinophil. The intact cellular miracidium is seen inside the ovum. The lobular structure and normal hepatocytes are disrupted by the multiple granulomas. Treated groups exhibited an obvious improvement; a small hepatic fibro cellular granuloma with markedly degenerated miracidium was noticed and the granuloma contour is regular and well-demarcated from the surrounding tissue, (Fig. 3). Masson's trichrome staining display variation in the distribution of collagen fibers in different treated groups. The collagen fibers were increased around, inside and pre- granuloma of hepatic tissue in untreated infected group. A marked reduction in the collagen fibers was observed in DWE+PZQ treated group, then PZQ-treated group, followed by group treated with DWE only.

Liver sections from a treated group with DWE+PZQ revealed a decrease in the fibrosis concentrated around the trapped *S. mansoni* ova and accompanied by many fibroblasts more than groups treated with PZQ or DWE (Fig. 4). Furthermore, Hepatocyte adjacent to granuloma showed hydropic changes, focal a typical hyperplasia, vacuolar degeneration, necrotic foci, and hypereosinophilia. Central and portal veins were dilated and congested with infiltration of inflammatory cells. Kupffer cells were increased inside dilated liver sinusoids (Fig.5). These histopathological changes were reduced in all treated groups, where the organization of liver architecture was partially restored, and most hepatocytes appeared to be normal, especially in the group treated with combination of DWE and PZQ while the groups treated with PZQ or DWE demonstrated partial improvement of liver tissue (Fig.6).

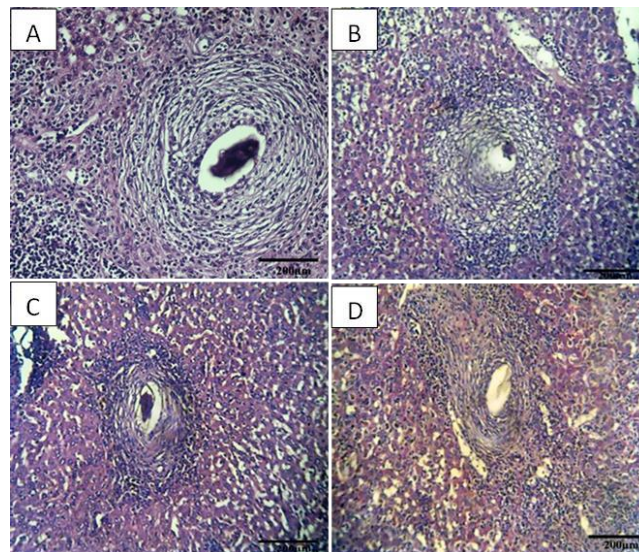


Fig. 3: Photomicrographs of liver granuloma in: (A) *S. mansoni* infected mice, illustrating large cellular granuloma composed of a mixture of chronic inflammatory cells rich in eosinophil. The intact cellular miracidium is seen inside the ovum. (B) representative of the PZQ group showing a small hepatic fibro cellular granuloma with markedly degenerated miracidium. (C): group treated with DWE showing a small hepatic fibro cellular granuloma with fewer inflammatory cells and markedly no degenerated miracidium. The granuloma contour is regular and well-demarcated from the surrounding tissue. (D): group treated with DWE+PZQ illustrating a fibro cellular granuloma with densely packed inflammatory cells and showing a small hepatic fibro cellular granuloma with markedly degenerated miracidium. H&E x100

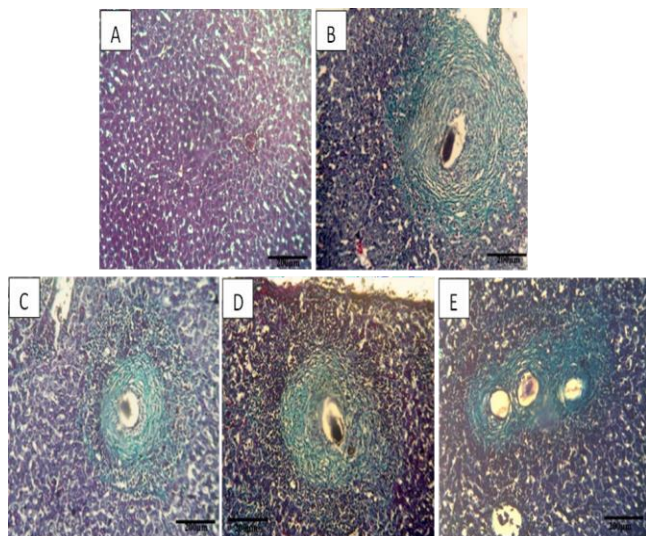


Fig. 4: Photomicrographs of liver sections stained with Masson trichrome from; (A) normal uninfected group showing normal minimal collagen fibers between hepatocyte, (B): infected group (IC) showing cellular extensive fibrosis around ova. (C) group treated with PZQ showing diminished cellular fibrosis around degenerated ova. (D): group treated with DWE showing moderate amount of collagen fibers around ova. (E) group treated with DWE + PZQ showing diminished cellular fibrosis around degenerated ova. H&E x100

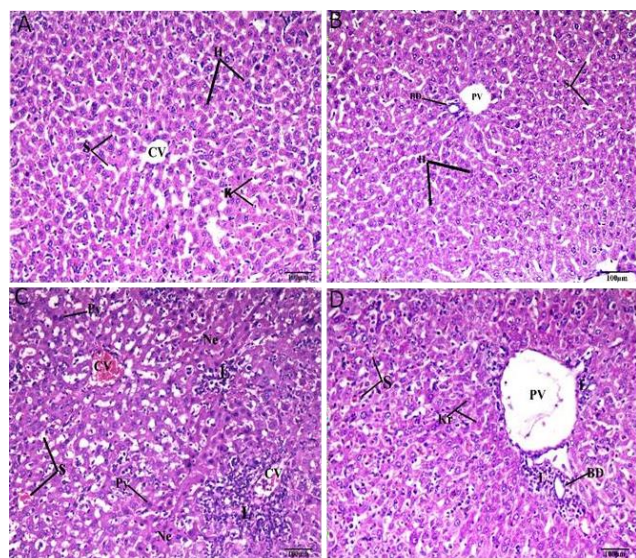


Fig. 5: Photomicrograph of Liver section from; (A, B) normal control group showing normal hepatic architecture, normal hepatocyte (H), central vein (CV), sinusoids (S), Kupffer cells (K), bile duct (BD) and Portal vein (PV). (C, D) infected mice with *S. mansoni* showing hydropic changes, necrotic areas (Ne) accompanied with inflammatory cell infiltrations (L), Pyknotic nuclei (Py) and few Karyolysis (K), dilation

and congestion of sinusoids (S). Also, dilated and congested of central vein (CV) and portal vein (PV) surrounded by lymphocyte infiltration (L), proliferation of bile ductless (BD) are noticed. H&E, x200

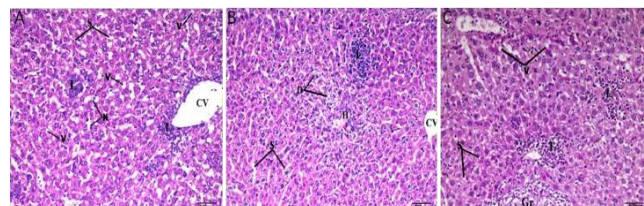


Fig. 6: Photomicrograph of Liver section from; (A) group treated with PZQ showing little vacuoles (v), proliferation of Kupffer cells (K), moderate congestion of hepatic sinusoids (s) and lymphocyte infiltration (L) between hepatocyte and around central vein (CV). (B) group treated with DWE showing partially improvement of hepatocyte, few lymphocytes infiltration (L) cytoplasm degeneration in some area of hepatic tissue (D) and hemolysis (H). Noticed normal hepatic sinusoids (s) and normal central vein (CV). (C) group treated with DWE+ PZQ showing normal hepatocytes architecture, normal hepatic sinusoids (s) little vacuoles (V) and lymphocytes infiltration (L) around blood vessels and between hepatocyte (L). Noticed part of Granuloma (Gr). H&E, X 200

Discussion:

In the present study, an aqueous extract of *T. officinale* leaves was examined against schistosomiasis. The most abundant phenolics acid and flavonoids in the investigated sample were rosmarinic acid, Quercetin, and then Gallic acid. These polyphenolic compounds are secondary metabolites that are commonly found in plant-derived foods. They have attracted considerable interest due to their many potential health benefits, which are powerful antioxidants and have been reported to demonstrate antiviral, antibacterial, anti-inflammatory, anticarcinogenic, and vasodilatory actions (Ivanova et al., 2005). Antioxidant activities of plant extracts were usually explained by the presence of phenolic acids in them (Ivanov et al., 2014; Diaz et al. 2018). Plants of the Asteraceae family are known to have hepatoprotective effects (Asadi-Samani et al., 2015 ; Sharifi-Rad et al., 2018). Emerging evidence suggests that *T. officinale* and its constituents have antioxidant and anti-inflammatory activities, resulting in diverse biological effects (González-Castejon et al., 2012).

In the present study, the group treated with a combination of (DWE + PZQ) showed high significant reduction ($p < 0.001$) in worm burden, means of egg count, and egg

development (Oogram) than PZQ-treated group followed finally the dandelion extract treated group (DWE) as compared to the infected untreated group (IC). These results coincided with that of (Atwa et al., 2022) who reported that oral administration of root extract dandelion only showed some anthelmintic activity as it caused a reduction in the parasitological parameters (worm burden and ova count) by nearly half as compared to the corresponding untreated infected group. The decrease of egg tissue load in treated mice might be due to the decrease in the burden of total worms after treatment, the low female productivity, and the host's tissue reaction that actively destructed the few produced eggs (Mostafa and Saved, 2001).

Vale et al. (2017) showed that praziquantel (PZQ) is the best drug for the treatment of schistosomiasis. (Abdul Ghani et al., 2009) documented that PZQ and derivatives of artesunate were shown to be effective against different stages of worm development. Praziquantel has direct effects on the schistosomes, producing contraction of the worm's musculature (Pax et al., 1978), an influx of calcium into the worms (Wolde-Mussie et al., 1982), and disruption of the tegument (Bricker et al., 1983). These drugs often interfere with the main targets in the parasites such as membrane integrity, microtubules, DNA, and neuronal signal transduction (Wink, 2012). It also depends on the host immune system for killing the parasite in vivo (Melhorn et al., 1981) and excellent therapeutic effects and is well tolerated by patients (Smith et al., 1981).

Disturbance in the cellular antioxidant mechanism and liberation of free radicals is a manifestation of schistosomiasis and is associated with established infection, the host immune system generates oxidative stress and liberates oxygen-derived free radicals as a non-specific initial defense to counteract the antioxidant defense mechanism of the parasite (Aragon et al., 2008).

Panda and Luyten (2018) showed that the Asteraceae family contains many phenols, which discourage many parasites. Antiparasitic activity of the Asteraceae can suppress protozoan parasites such as *Trypanosoma spp.*, *Leishmania spp.*, *Plasmodium spp.*, and intestinal worms. *Taraxacum officinale* (Dandelion) is a member of the Asteraceae family that can have a wide range of pharmacological properties and applications and is a promising natural medicine in the treatment of chronic liver diseases such as hepatic steatosis and hepatitis (Devaraj, 2016).

Laquale et al. (2018) showed the activity of the Asteraceae species *T. officinale* against the root-knot nematode. Root and leaf extracts of *T. officinale* induce egg hatchability reduction at the maximum concentration of root and leaf extracts. Soil treatments with *T. officinale*

root and leaf material strongly suppressed nematode multiplication. Rosemarinic acid was the major polyphenolic compound that can be responsible for therapeutic properties due to has powerful antioxidant and anti-inflammatory properties (Rahbardar et al., 2017). The high yield of rosemarinic acid makes this plant a valuable source of commercial production (Ivanov, 2014).

Faria et al. (2019) and Aabideen et al. (2020) showed that *Taraxacum officinale* leaves are rich sources of polyphenols and possess high antioxidant properties. *T. officinale* is used to treat liver disorders, and inflammations, with potential for the anti-bacterial, cytotoxic, antiviral, antiparasitic, and antifungal activity. The polyphenolic fraction from aerial parts of dandelion collected during different vegetative stages demonstrated higher antimicrobial activity. The extract with a concentration (1mg/ml) possessed moderate inhibitory activity against the Gram-positive microorganism. In addition, the extract obtained after flowering showed the highest antimicrobial activity which corresponded to the highest polyphenolic content and antioxidant activity of the same dandelion extract (Ivanov et al., 2018).

Rajamanickam and Muthuswamy, (2008) reported that the liver has a vital role in general metabolism and hepatic damage can affect the metabolic processes in the body. Enzymes are necessary for normal cellular metabolism. Hepatoprotective activity of dandelion was evaluated on *S. mansoni* infected mice by estimation of serum hepatic enzymes. Infection of *S. mansoni* damages the hepatic cells leading to a significant increase in serum levels of AST, and ALT. The marked increase in the serum marker enzymes, AST and ALT, may related to the cell membrane damage (Naik et al., 2011). Treated group with DWE+ PZQ showed high significant reduction of AST, and ALT enzymes compared to sole treatment of PZQ. These results agree with (Atwa et al., 2022) who stated that combined treatment of PZQ and dandelion root extract showed the most pronounced reduction in serum ALT and AST levels followed by PZQ treated group. This amelioration in the activities of liver enzymes could be attributed to the reduction in hepatic granuloma size and fibrosis as well as absence of necrotic hepatic tissue in infected treated mice (Allam, 2009). The reduction of elevated liver enzymes may be related to inhibition of the inflammatory markers response that decreases liver inflammation and hence inhibits liver transaminases (ALT, AST) activities (Mahboubi and Mahboubi, 2020).

Serum level of albumin in untreated infected mice was reduced significantly as compared to normal uninfected group. the reduction in blood total protein could be attributed to the structural damage of liver cells and deteriorations in cells' metabolic processes exerted by the parasites' ova in the liver and intestine of the infected

hosts (Tag et al., 2020). However, Supplementation of DWE+PZQ to infected mice resulted in an elevation of albumin level compared with untreated infected mice. A moderate improvement of the tested biochemical parameters in the infected treated mice agrees with that of mice groups infected with *S. mansoni* and treated with either thymoquinone (Saleh et al., 2005) or artemether (Botros et al., 2007).

Hfaiedh et al. (2016) The hepatoprotective effects of dandelion leaves extract were confirmed against sodium dichromate induced liver injury in rats. Oral daily administration of dandelion leaves hot water extract (500 mg/kg) for 30 d decreased the total cholesterol, triglycerides, AST, ALT, lactate dehydrogenase, MDA and chromium concentration in rat's blood and liver. Dandelion leaves extract is associated with increase in antioxidant enzymes activities (GSH, SOD, catalase, GPX levels) and reduction in lipid peroxidation, GST, formation of atherosclerotic lesions (Choi et al., 2010) and DNA fragmentation (Hamzawy et al., 2015). Up-regulation of hepatic antioxidant enzymes may be responsible for its hepatoprotective effects.

Among different parts of dandelion extracts, aqueous extracts of dandelion roots and leaves have been used as hepatoprotective agents. Different components may be responsible for its hepatoprotective effects. Total phenolics, flavonoids, tannins, polysaccharides, and ascorbic acids are the main components of the hot aqueous extract of dandelion leaves with the ability to scavenge the free radicals (Hfaiedh et al., 2016)

In the present study, the combined DWE + PZQ treated group showed the highest significant reduction in the number and size of hepatic granulomas, then PZQ treated group, and finally, DWE treated group as compared to the infected untreated group. These results indicated the remarkable ameliorative impact of dandelion extract with PZQ in the histological findings. Kabuyaya et al. (2018) stated that praziquantel is a potent antiparasitic drug, however, it cannot treat liver fibrosis that is accompanied by schistosomiasis. The reduction in hepatic granuloma number is attributed to the reduction in ova count/tissue, while the reduction in granuloma diameter could be attributed to the anti-inflammatory and anti-fibrotic properties of dandelion due to its high content of phytosterols, and sesquiterpene lactones (Atwa et al., 2022).

Histopathological study of infected group revealed marked inflammatory reaction with large granuloma around the ovum and diminished in size in all treated group. This was in accordance with Chesney et al. (1998) who described the infiltration of circulating fibroblasts into granulomas and speculated that these cells may be

important for attracting lymphocytes as well as forming collagen.

Schistosomiasis manifestations were mainly attributed to granulomatous inflammation around the parasite eggs (Abath et al., 2006). Granulomas develop around the ova within different tissues of the host including liver. The egg shell protects the ova from destruction by the host defense mechanisms. The ova release a variety of substances which are toxic to host tissues and antigenic, leading to antigen-specific humoral and cell mediated immune responses. The formation of granulomas in the liver is a manifestation of delayed type hypersensitivity to soluble egg antigens, which are released by the trapped ova (Elbaz and Esmat, 2013). Although granuloma formation is beneficial for the host because it blocks the hepatotoxic effects of antigens released from parasitic eggs, this process may lead to fibrosis with excessive accumulation of collagen and extracellular matrix proteins in the periportal areas (Morais et al., 2008). Granuloma formation is a protective phenomenon for the host as it sequesters toxic and antigenic substances and eventually it destroys the egg and removes residual debris. Deleterious effects of granulomas include focal tissue injury and induction of noticeable fibrosis. Granulomas contain macrophages, epithelioid cells, giant cells, eosinophils, lymphocytes, and a few mast cells. The inflammatory cells rest on collagenous matrix produced by fibroblasts. This matrix displaces normal organ parenchyma (Weinstock, 1992).

Although the current study reported moderate antifibrotic action of PZQ, opposing results were reported by Liang et al. (2011), they recorded antifibrotic and hepatoprotective effects of PZQ in *S. japonicum* infected mice. Their results were obtained after 30 days of continuous PZQ treatment. Restoring normal hepatic organization and hepatocyte appearance in group treated with DWE + PZQ may be due to the potent antioxidant effect of dandelion, and its ability to scavenge free radicals (Sakr and Saber, 2007).

In addition, this may be attributed to Th1 and Th2 lymphocytes suppression with subsequent decrease in related cytokines, which play a major role in the formation of granuloma as mentioned by (Wynn and Cheever, 1995). The aqueous extract of *Taraxacum officinale* has been elucidated by having strong antiangiogenic, anti-inflammatory, and antinociceptive activities, that is, capable of minimizing the production of nitric oxide (NO) and cyclooxygenase 2 (COX-2) and decrease the rate of reactive oxygen species (ROS) in cells activated macrophages (González-Castejón et al., 2012). Other than the antioxidant activities and the anti-fibrotic effects of dandelion aqueous extract have been confirmed, dandelion inactivates the hepatic stellate cells

and enhances the hepatic regenerative capabilities (Colle et al., 2012).

Park et al. (2010) reported that DWE protection against hepatic damage induced by CCl₄ is achieved through the modulation of inflammatory responses, and oxidative status thus dandelion leaves water extract (DLWE) seems to be an efficient therapeutic agent that prevents and treats CCl₄-induced hepatic injury. Al-Malki and Abo-Golayel, (2013) indicated that supplementation of DLWE could improve significantly ($P < 0.01$) the portal inflammation, necrosis, fibrosis and steatosis at the end of 6th week of the study compared to that of the CCl₄ treated rats at the end of the same studied week. Polyphenols, flavonoids, and polysaccharides are responsible compounds for hepatoprotective effects of dandelion. Therefore, the dandelion extracts can be standardized based on one of these compounds (Mahboubi and Mahboubi, 2020).

Owing to its widespread use and pharmacological potential, several studies have been conducted to identify the constituents of *T. officinale*. These compounds have been identified in subsequent studies and the present study mainly as phenolic acids and flavonoids (Williams et al., 1996 and Hu and Kitts, 2003). Among these compounds, Rosmarinic acid that plays diverse roles as an antioxidant and in the prevention of inflammation (Hu and Kitts, 2003; Dalby-Brown et al., 2005).

Mead and McNair (2006) also studied the antiparasitic activity of flavonoids and isoflavones against *Cryptosporidium parvum* and *Encephalitozoon intestinalis*. These authors also found that quercetin and apigenin had activity against *E. intestinalis*. It is known that oxidative stress due to schistosomiasis at the site of granulomatous inflammation leads to the generation of lipid peroxidation (LPO) products, which may play a central role in the pathology of schistosomiasis (Aly et al., 2010). LPO products cause cell injury and necrosis due to losing the fluidity and integrity of cell membrane (Dkhil et al., 2014).

Qiao et al. (2005) concluded that lipopolysaccharide-induced NO and iNOS protein were inhibited by rosmarinic acid. Carbon tetrachloride induced liver injury was prevented in rats treated with essential oil of rosmarinic acid through radical scavenging activity as well as normalizing antioxidant enzymes catalase, peroxidase, glutathione peroxidase and glutathione reductase in the liver tissue of animals (Raskovic et al., 2014). Rosmarinic acid has many biological activities, such as inhibiting the HIV-1, antitumor, and anti-hepatitis as well as protecting the liver, inhibition of blood clots, and anti-inflammation (Tepe, 2008; Aldoghachi et al., 2021). Anthelmintic

therapy derived from medicinal plants is a promising source of effective treatment (Liu et al., 2020).

Conclusion:

According to our results, when used dandelion water extract only gave a less effective result, but when combined with the PZQ the most effective in all parameters were achieved. Dandelion leaves water extract can be added as a potential treatment against schistosomiasis when combined with the anti-schistosomal drug praziquantel.

REFERENCES

1. Aabideen, Z.U., Mumtaz, M.W., Akhtar, M.T., Mukhtar, H., Raza, S.A., Touqeer, T., & Saari, N. (2020). Anti-obesity attributes; UHPLC-QTOF-MS/MS-based metabolite profiling and molecular docking insights of *Taraxacum officinale*. *Molecules* 25(4935):1–20.
2. Abath, F.G., Morais, C.N., Montenegro, C.E., & Wynn, T.A. (2006). Montenegro SM Immunopathogenic mechanisms schistosomiasis: what can be learnt from human studies? *Trends Parasitol.* 22: 85-91.
3. Abdul-Ghani, R. A., Loutfy, N., & Hassan, A. (2009). Experimentally promising antischistosomal drugs: a review of some drug candidates not reaching the clinical use. *Parasitology research*, 105(4), 899-906.
4. Abdulla, M.H., Lim, K.C., Sajid, M., McKerrow, J.H., & Caffrey, C.R. (2007). Schistosomiasis mansoni: novel chemotherapy using a cysteine protease inhibitor. *PLoS Med* 4:0130–0138.
5. Abu Almaaty, A., Rashed, H., Soliman, M. F., & El-Shenawy, N. S. (2021). Effect of Praziquantel, Allicin, and Curcumin on The Histology of Liver, Spleen, and Kidney of *Schistosoma mansoni* Infected Mice. *Egyptian Journal of Histology*, 44(2), 465-477.
6. Ahmed, D., Gulfranz, M., Ahmad, M. S., Tahir, R. M., & Anwar, P. (2013). Cytoprotective potential of methanolic leaves extract of *Taraxacum officinale* on CCl₄ induced Rats. *Pensee J*, 75(10), 220-227.
7. Aldoghachi, F.E.H., Noor Al-Mousawi, U.M., & Shari, F.H. (2021). Antioxidant Activity of Rosmarinic Acid Extracted and Purified from *Mentha piperita*. *Arch Razi Inst.* 2021 Nov 30;76(5):1279-1287.
8. Allam, G. (2009). Immunomodulatory effects of curcumin treatment on murine schistosomiasis mansoni. *Immunobiology*, 214(8), 712-727.
9. Al-Malki, A.L., & Abo-Golayel, M.K. (2013). Hepatoprotective efficacy of chicory alone or combined with dandelion leaves against induced liver damage. *Life Sci. J.* 2013;10(4):140-157.
10. Aly, I.R., Hendawy, M.A., Ali, E., Hassan, E., Nosseir, M.M. (2010). Immunological and parasitological parameters after treatment with dexamethasone in murine *Schistosoma mansoni*. *Memorias do Instituto Oswaldo Cruz.* 105: 729- 35.
11. Aragon, A. D., Imani, R. A., Blackburn, V. R., & Cunningham, C. (2008). Microarray based analysis of temperature and oxidative stress induced messenger RNA in *Schistosoma mansoni*. *Molecular and biochemical parasitology*, 162(2), 134-141.
12. Arpadjan, S., Çelik, G., Taşkesen, S., & Güçer, Ş. (2008). Arsenic, cadmium and lead in medicinal herbs and their fractionation. *Food and chemical toxicology*, 46(8), 2871-2875.
13. Asadi-Samani, M., Kafash-Farkhad, N., Azimi, N., Fasihi, A., Alinia-Ahandani, E., & Rafeiean-Kopaei, M. (2015). "Medicinal plants with hepatoprotective activity in Iranian folk medicine," *Asian Pacific Journal of Tropical Biomedicine*, vol. 5, no. 2, pp. 146–157.

14. Atwa, M. T. M., Abd-Elrazek, A. M., & Salem, N. I. (2022). Dandelion (*Taraxacum officinale*) Improves the Therapeutic Efficiency of Praziquantel in Experimental Schistosomiasis. *Acta Parasitologica*, 67(2), 773-783.
15. Basha, H., & Mamo, H. (2021). The Activity of Plant Crude Extracts against *Schistosoma mansoni*. *Journal of Parasitology Research*, 2021.
16. Bishayee, A., Sarkar, A., & Chatterjee, M. (1995). Hepatoprotective activity of carrot (*Daucus carota* L.) against carbon tetrachloride intoxication in mouse liver. *Journal of ethnopharmacology*, 47(2), 69-74.
17. Botros, S., Mahmoud, M.R., & Nossier, M.M. (2007). Immunohistopathological and biochemical changes in *Schistosoma mansoni* infected mice treated with Artemether. *J Infect* 2007;55:470-7.
18. Bricker, C. S., Depenbusch, J. W., & Bennett, J. L. (1983). Tegumental disruption of *S. mansoni* caused by praziquantel and Ro 11-3128. *Z Parasitenk*, 69, 61-71.
19. Chesney, R. W., Helms, R. A., Christensen, M., Budreau, A. M., Han, X., & Sturman, J. A. (1998). The role of taurine in infant nutrition. *Taurine* 3, 463-476.
20. Choi, U.K., Lee, O.H., Yim, J.H., Cho, C.W., Rhee, Y.K., Lim, S.I., et al. (2010). Hypolipidemic and antioxidant effects of dandelion (*Taraxacum officinale*) root and leaf on cholesterol-fed rabbits. *Int J Mol Sci* 2010; 11(1): 67-78.
21. Colle, D., Arantes, L.P., Gubert, P., da Luz, S.C., & Athayde, M.L. (2012). Teixeira Rocha JB, et al. Antioxidant properties of *Taraxacum officinale* leaf extract are involved in the protective effect against hepatotoxicity induced by acetaminophen in mice. *J Med Food* 2012; 15(6): 549-556.
22. Dalby-Brown, L., Barsett, H., Landbo, A.-K. R., Meyer, A. S., & Mølgaard, P. (2005). "Synergistic antioxidative effects of alkamides, caffeic acid derivatives, and polysaccharide fractions from *Echinacea purpurea* on in vitro oxidation of human lowdensity lipoproteins," *Journal of Agricultural and Food Chemistry*, vol. 53, no. 24, pp. 9413-9423.
23. Danso-Appiah, A., & De Vlas, S. J. (2002). Interpreting low praziquantel cure rates of *Schistosoma mansoni* infections in Senegal. *Trends in parasitology*, 18(3), 125-129.
24. Delafield, F. (1984). Haematoxylin and Eosin for General Staining. *Staining of the animal Tissues Practical and Theoretical*. Oxford University Press, London.
25. Devaraj, E. (2016). Hepatoprotective properties of dandelion: recent update. *J Appl Pharm Sci* 6:202-205.
26. Diaz, K., Espinoza, L., Madrid, A., Pizarro, L., & Chamy, R. (2018). Isolation and identification of compounds from bioactive extracts of *Taraxacum officinale* Weber ex F. H. Wigg. (dandelion) as a potential source of antibacterial agents. *Evid Based Complement Alternat Med*. 8:1-8.
27. Dkhil, M.A., Moneim, A.E.A., Al-Quraishy, S. (2014). Berberine protects against *Schistosoma mansoni*- induced oxidative damage in renal and testicular tissues of mice. *Pakistan J. Zoology* 46:763-771.
28. Duvall, R. H., & DsWitt, W. B. (1967). An improved perfusion technique for recovering adult schistosomes from laboratory animals. *American Journal of Tropical Medicine and Hygiene*, 16(4), 483-486.
29. Elbaz, T., & Esmat, G. (2013). Hepatic and intestinal schistosomiasis. *Journal of advanced research*, 4(5), 445-452.
30. El-Lakkany, N. M., Hammam, O. A., El-Maadawy, W. H., Badawy, A. A., Ain-Shoka, A. A., & Ebeid, F. A. (2012). Anti-inflammatory/anti-fibrotic effects of the hepatoprotective silymarin and the schistosomicide praziquantel against *Schistosoma mansoni*-induced liver fibrosis. *Parasites & vectors*, 5(1), 1-14.
31. Escudero, N. L., De Arellano, M. L., Fernández, S., Albarracín, G., & Mucciarelli, S. (2003). *Taraxacum officinale* as a food source. *Plant Foods for Human Nutrition*, 58(3), 1-10.
32. Ezhilarasan, D., Karthikeyan, S., & Vivekanandan, P. (2012). Ameliorative effect of silibinin against N-nitrosodimethylamine-induced hepatic fibrosis in rats. *Environmental toxicology and pharmacology*, 34(3), 1004-1013.
33. Ezhilarasan, D., Sokal, E., Karthikeyan, S., & Najimi, M. (2014). Plant derived antioxidants and antifibrotic drugs: past, present and future. *J Coast Life Med*, 2(9), 738-745.
34. Faria, T. C., Nascimento, C. C. H. C., De Vasconcelos, S. D. D., & Stephens, P. R. S. (2019). Literature review on the biological effects of *Taraxacum officinale* plant in therapy. *Asian Journal of Pharmaceutical Research and Development*, 7(3), 94-99.
35. Freire, N., Rodrigues-Silva, R., Machado-Silva, J. R., & Rey, L. (2003). A comparative parasitologic study on *Biomphalaria glabrata* snail and C3H/He mice infected with human and murine isolates of *Schistosoma mansoni* derived from Sumidouro, Rio de Janeiro, Brazil. *Memórias do Instituto Oswaldo Cruz*, 98, 783-787.
36. González-Castejón, M., Visioli, F., & Rodríguez-Casado, A. (2012). Diverse biological activities of dandelion. *Nutrition reviews*, 70(9), 534-547.
37. Gorchakov, V.V., & Vorotnikov, V.P. (2017). Anthelmintic activity of dandelion (*Taraxacum officinale* Wigg.). *Agricultural Science Euro-North-East*. 2017;(2):57-61. (In Russ.).
38. Gulfraz, M., Ahamd, D., Ahmad, M. S., Qureshi, R., Mahmood, R. T., Jabeen, N., & Abbasi, K. S. (2014). Effect of leaf extracts of *Taraxacum officinale* on CCl₄ induced Hepatotoxicity in rats, in vivo study. *Pakistan journal of pharmaceutical sciences*, 27(4).
39. Hamzawy, M.A., El-Denshary, E.S., & Abdel-Wahhab, M.A. (2015). Effects of natural compounds in treatment and prevention of hepatotoxicity and hepatocellular carcinoma. *Hepatology Res* 2015; 1: 111-118.
40. Henry, R.J., Cannon, D.C., & Winkelman, J.W. (1974). *Clinical chemistry: Principles and techniques*. Harper and Row, New York.
41. Herbert, D.R., Orekov, T., Roloson, A., Ilies, M., Perkins, C., O'Brien, W., Cederbaum, S., Christianson, D.W., Zimmermann, N., Rothenberg, M.E., Finkelman, F.D. (2010). Arginase I suppresses IL-12/IL-23p40- driven intestinal inflammation during acute schistosomiasis. *Immunol. J.* 184 (11), 6438- 6446.
42. Hfaiedh, M., Brahmi, D., & Zourgui, L. (2016). Hepatoprotective effect of *Taraxacum officinale* leaf extract on sodium dichromate-induced liver injury in rats. *Environ Toxicol* 2016; 31(3): 339-349.
43. Hu, C. (2018). *Taraxacum*: Phytochemistry and health benefits. *Chinese Herbal Medicines*, 10(4), 353-361.
44. Hu, C., & Kitts, D. D. (2003). "Antioxidant, prooxidant, and cytotoxic activities of solvent-fractionated dandelion (*Taraxacum officinale*) flower extracts in vitro," *Journal of Agricultural and Food Chemistry*, vol. 51, no. 1, pp. 301-310.
45. Humason, G.L. (1972). *Animal Tissue Technique*. W.H. Freeman and Company, San Francisco.
46. Ibrahim, K. E., Al-Mutary, M. G., Bakhiet, A. O., & Khan, H. A. (2018). Histopathology of the liver, kidney, and spleen of mice exposed to gold nanoparticles. *Molecules*, 23(8), 1848.
47. Ivanov, I. G. (2014). Polyphenols content and antioxidant activities of *Taraxacum officinale* FH Wigg (dandelion) leaves. *International journal of pharmacognosy and phytochemical research*, 6(4), 889-893.
48. Ivanov, I., Petkova, N., Tumbarski, J., Dincheva, I., Badjakov, I., Denev, P., & Pavlov, A. (2018). GC-MS characterization of n-hexane soluble fraction from dandelion (*Taraxacum officinale* Weber ex FH Wigg.) aerial parts and its antioxidant and antimicrobial properties. *Zeitschrift für Naturforschung C*, 73(1-2), 41-47.
49. Ivanov, I., Vrancheva, R., Marchev, A., Petkova, N., Aneva, I., Denev, P., ... & Pavlov, A. (2014). Antioxidant activities and phenolic compounds in Bulgarian *Fumaria* species. *International Journal of Current Microbiology and Applied Sciences*, 3(2), 296-306.
50. Ivanova, D., Gerova, D., Chervenkov, T., & Yankova, T. (2005). Polyphenols and antioxidant capacity of Bulgarian medicinal plants. *Journal of ethnopharmacology*, 96(1-2), 145-150.
51. Jacobs, W., Bogers, J., Deelder, A., Wery, M., & Van Marck, E. (1997). Adult *Schistosoma mansoni* worms positively modulate soluble egg antigen-induced inflammatory hepatic granuloma formation in vivo. *Stereological analysis and*

- immunophenotyping of extracellular matrix proteins, adhesion molecules, and chemokines. *The American journal of pathology*, 150(6), 2033-2045.
52. Jeon, D., Kim, S. J., & Kim, H. S. (2017). Anti-inflammatory evaluation of the methanolic extract of *Taraxacum officinale* in LPS-stimulated human umbilical vein endothelial cells. *BMC complementary and alternative medicine*, 17(1), 1-10.
 53. Kabuyaya, M., Chimbari, M. J., & Mukaratirwa, S. (2018). Efficacy of praziquantel treatment regimens in pre-school and school aged children infected with schistosomiasis in sub-Saharan Africa: a systematic review. *Infectious diseases of poverty*, 7(1), 1-7.
 54. Laquale, S., Avato, P., Argentieri, M. P., Candido, V., Perniola, M., & D'Addabbo, T. (2018). Nematicidal potential of *Taraxacum officinale*. *Environmental Science and Pollution Research*, 25(30), 30056-30065.
 55. Liang, Y. J., Luo, J., Yuan, Q., Zheng, D., Liu, Y. P., Shi, L., & Zhang, Z. S. (2011). New insight into the antifibrotic effects of praziquantel on mice in infection with *Schistosoma japonicum*. *PLoS One*, 6(5), e20247.
 56. Lis, B., & Grabek-Lejko, D. (2016). Mniszek lekarski (*Taraxacum officinale*)—potencjalne właściwości prozdrowotne. *Nauka Przyroda Technologie*, 10(3), 37.
 57. Lis, B., Jędrejek, D., Stochmal, A., & Olas, B. (2018). Assessment of effects of phenolic fractions from leaves and petals of dandelion in selected components of hemostasis. *Food research international*, 107, 605-612.
 58. Liu, M., Panda, S. K., & Luyten, W. (2020). Plant-based natural products for discovery and development of novel anthelmintics against nematodes. *Biomolecules*.
 59. Mahboubi, M., & Mahboubi, M. (2020). Hepatoprotection by dandelion (*Taraxacum officinale*) and mechanisms. *Asian Pac J Trop Biomed* 1:1-10.
 60. Mahmoud, T. Y., Rizk, S. M., Maghraby, A. S., & Shaheen, A. A. (2014). Propolis enhances the effectiveness of praziquantel in experimental schistosomiasis: biochemical and histopathological study. *Parasitology research*, 113(12), 4513-4523.
 61. Mahmoud, Y. I., Riad, N. H., & Taha, H. (2016). Garlic attenuates histological and histochemical alterations in livers of *Schistosoma mansoni* infected mice. *Biotechnic & Histochemistry*, 91(6), 389-395.
 62. Mead, J.R., & McNair, N. (2006). Antiparasitic activity of flavonoids and isoflavones against *Cryptosporidium parvum* and *Encephalitozoon intestinalis*. *FEMS Microbiology Letters*, 259, 153-157.
 63. Mehlhorn, H. B. P. H. J., Becker, B., Andrews, P., Thomas, H., & Frenkel, J. K. (1981). In vivo and in vitro experiments on the effects of praziquantel on *Schistosoma mansoni*. A light and electron microscopic study. *Arzneimittel-forschung*, 31(3a), 544-554.
 64. Miao, E. A., Leaf, I. A., Treuting, P. M., Mao, D. P., Dors, M., Sarkar, A., & Aderem, A. (2010). Caspase-1-induced pyroptosis is an innate immune effector mechanism against intracellular bacteria. *Nature immunology*, 11(12), 1136-1142.
 65. Modaresi, M., & Resalatpour, N. (2012). The effect of *Taraxacum officinale* hydroalcoholic extract on blood cells in mice. *Advances in hematology*, 2012.
 66. Morais, C.N., Souza, J.R., Melo, W.G., Aroucha, M.L., Miranda, P., Domingues, A.L., et al. (2008). Cytokine profile associated with chronic and acute human schistosomiasis mansoni. *Mem Inst Oswaldo Cruz*; 103: 561-568.
 67. Mostafa, O., & Saved, M. (2001). Experimental use of black-seed oil against schistosoma majsojvtin albino mice. i. some parasitological and biochemical parameters. *Egyptian Journal of Medical Laboratory Sciences*, 10(2), 99-113.
 68. Mostafa, O., Eid, R. A., & Adly, M. A. (2011). Antischistosomal activity of ginger (*Zingiber officinale*) against *Schistosoma mansoni* harbored in C57 mice. *Parasitology Research*, 109(2), 395-403.
 69. Naik, S. R., Thakare, V. N., & Patil, S. R. (2011). Protective effect of curcumin on experimentally induced inflammation, hepatotoxicity and cardiotoxicity in rats: evidence of its antioxidant property. *Experimental and Toxicologic Pathology*, 63(5), 419-431.
 70. Nelwan, M. L. (2019). Schistosomiasis: life cycle, diagnosis, and control. *Current Therapeutic Research*, 91, 5-9.
 71. Nowak, A., Duchnik, W., Zielonka-Brzezicka, J., Muzykiewicz, A., Florkowska, K., Klimowicz, A., & Dziedzic, A. (2019). The antioxidant activity of ethanolic and aqueous extracts of dandelion (L.). *Pomeranian Journal of Life Sciences*, 65(4), 83-88.
 72. Panda, S. K., & Luyten, W. (2018). Antiparasitic activity in Asteraceae with special attention to ethnobotanical use by the tribes of Odisha, India. *Parasite*, 25.
 73. Park, C. M., Cha, Y. S., Youn, H. J., Cho, C. W., & Song, Y. S. (2010). Amelioration of oxidative stress by dandelion extract through CYP2E1 suppression against acute liver injury induced by carbon tetrachloride in sprague dawley rats. *Phytotherapy Research*, 24(9), 1347-1353.
 74. Pax, R., Bennett, J. L., & Fetterer, R. (1978). A benzodiazepine derivative and praziquantel: effects on musculature of *Schistosoma mansoni* and *Schistosoma japonicum*. *Naunyn-Schmiedeberg's archives of pharmacology*, 304(3), 309-315.
 75. Pellegrino, J., & Goncalves, M. (1965). A simple method for collecting egg clutches of *Biomphalaria glabrata* (*Australorbis glabratus*) and for rearing newly hatched snails. *Journal of Parasitology*, 51(6).
 76. Pellegrino, J., Oliveira, C. A., Faria, J., & Cunha, A. S. (1962). New approach to the screening of drugs in experimental schistosomiasis mansoni in mice. *American Journal of Tropical Medicine and Hygiene*, 11(2), 201-215.
 77. Peters, P. A., & Warren, K. S. (1969). A rapid method of infecting mice and other laboratory animals with *Schistosoma mansoni*: subcutaneous injection. *Journal of Parasitology*, 55(3).
 78. Pinnell, A. E., & Northam, B. E. (1978). New automated dye-binding method for serum albumin determination with bromocresol purple. *Clinical chemistry*, 24(1), 80-86.
 79. Qiao, S., Li, W., Tsubouchi, R., Haneda, M., Murakami, K., Takeuchi, F., ... & Yoshino, M. (2005). Rosmarinic acid inhibits the formation of reactive oxygen and nitrogen species in RAW264.7 macrophages. *Free radical research*, 39(9), 995-1003.
 80. Rahbardar, M. G., Amin, B., Mehri, S., Mirajafi-Zadeh, S. J., & Hosseinzadeh, H. (2017). Anti-inflammatory effects of ethanolic extract of *Rosmarinus officinalis* L. and rosmarinic acid in a rat model of neuropathic pain. *Biomedicine & Pharmacotherapy*, 86, 441-449.
 81. Rajamanickam, V., & Muthuswamy, N. (2008). Effect of heavy metals induced toxicity on metabolic biomarkers in common carp (*Cyprinus carpio* L.). *Mj. Int. J. Sci. Tech.*, 2(10): 192-200.
 82. Rašković, A., Milanović, I., Pavlović, N., Čebović, T., Vukmirović, S., & Mikov, M. (2014). Antioxidant activity of rosemary (*Rosmarinus officinalis* L.) essential oil and its hepatoprotective potential. *BMC complementary and alternative medicine*, 14(1), 1-9.
 83. Rollinson, D., Knopp, S., Levitz, S., Stothard, J. R., Tchuente, L. A. T., Garba, A., & Utzinger, J. (2013). Time to set the agenda for schistosomiasis elimination. *Acta tropica*, 128(2), 423-440.
 84. Sakr, S. A., & Saber, A. (2007). Ameliorative effect of ginger (*Zingiber officinale*) on mancozeb fungicide induced liver injury in albino rats. *Aust J Basic Appl Sci*, 1(4), 650-656.
 85. Saleh, S., Mahmoud, M., El-Abhar, H., & Omran, Z. (2005). Antischistosomal effect of thymoquinone in murine schistosomiasis mansoni: influence on nitric oxide, ICA-1 and collagen. *Kasr El-Aini Med J* 2005;11:117-27.
 86. Schutz, K., Carle, R., & Schieber, A. (2006). "Taraxacum--a review on its phytochemical and pharmacological profile," *Journal of Ethnopharmacology*, vol. 107, pp. 313-323.
 87. Sharifi-Rad, M., Roberts, T. H., Matthews, K. R., et al. (2018). "Ethnobotany of the genus *Taraxacum*-Phytochemicals and antimicrobial activity," *Phytotherapy Research*, vol. 32, pp. 2131-2145.
 88. Singh, A., Bhat, T. K., & Sharma, O. P. (2011). Clinical Biochemistry of Hepatotoxicity. *J Clinic Toxicol* S4: 001. doi: 10.4172/2161-0495. S4-001 *J Clinic Toxicol Clinical Pharmacology: Research & Trials* ISSN: 2161-0495 JCT, an open

access journal. *in vitro Systems*.

89. Smith, D.H., Highton, R.B., & Robert, I.M. (1981). Preliminary observations on the treatment of Schistosomiasis mansoni with Biltricide in Kenya. *Arzneimittel-Forschung/Drug Research* 31, 594–596.
90. Tag, H., Henedak, M. M., Abouelhassan, E. M., Hassan, E. A., & Zayed, R. A. (2020). Antioxidative and hepatoprotective effects of *Artemisia santonica* and *Origanum syriacum* against *Schistosoma mansoni* infection. *Journal of Applied Biological Sciences*, 14(1), 86-97.
91. Takasaki, M., Konoshima, T., Tokuda, K., Masuda, K., Arai, Y., Shiojima, K., & Ageta, H. (1999). Anti-carcinogenic activity of *Taraxacum* plant. II. *Biological and Pharmaceutical Bulletin*, 22(6), 606-610.
92. Tepe, B. (2008). Antioxidant potentials and rosmarinic acid levels of the methanolic extracts of *Salvia virgata* (Jacq), *Salvia staminea* (Montbret & Aucher ex Benth) and *Salvia verbenaca* (L.) from Turkey. *Bioresour Technol.* 2008; 99(6):1584-8.
93. Vale, N., Gouveia, M. J., Rinaldi, G., Brindley, P. J., Gärtner, F., & Correia da Costa, J. M. (2017). Praziquantel for schistosomiasis: single-drug metabolism revisited, mode of action, and resistance. *Antimicrobial agents and chemotherapy*, 61(5), e02582-16.
94. Weinstock, J.V. (1992). The pathogenesis of granulomatous inflammation and organ injury in schistosomiasis: interactions between the Schistosome ova and the host. *Immunol. Invest.* 21: 455-75.
95. Williams, C. A., Goldstone, F., & Greenham, J. (1996). "Flavonoids, cinnamic acids and coumarins from the different tissues and medicinal preparations of *Taraxacum officinale*," *Phytochemistry*, vol. 42, pp. 121–127.
96. Wink, M. (2012). Medicinal plants: a source of anti-parasitic secondary metabolites. *Molecules*, 17(11), 12771-12791.
97. Wolde Mussie, E., VandeWaa, J., Pax, R.A., Fetterer, R., & Bennett, J.L. (1982). *Schistosoma mansoni*: calcium efflux and effects of calcium-free media on responses of the adult male musculature to praziquantel and other agent-inducing contractions. *J Parasitol* 68: 48–52.
98. Wynn, T. A., & Cheever, A. W. (1995). Cytokine regulation of granuloma formation in schistosomiasis. *Current opinion in immunology*, 7(4), 505-511.
99. Yarnell, E., & Abascal, K. (2009). Dandelion (*Taraxacum officinale* and *T. mongolicum*). *Integrative Medicine*, 8(2), 35-38.
100. You, Y., Yoo, S., Yoon, H. G., Park, J., Lee, Y. H., Kim, S., & Jun, W. (2010). In vitro and in vivo hepatoprotective effects of the aqueous extract from *Taraxacum officinale* (dandelion) root against alcohol-induced oxidative stress. *Food and chemical toxicology*, 48(6), 1632-1637.
101. Zanatta, M. E. D., Miorando, D., Steffler, A. M., Roos, N., Ernetti, J., Predebon, A. J., & Roman Junior, W. A. (2021). Gastroprotective Effects of the Aqueous Extract from *Taraxacum officinale* in Rats Using Ultrasound, Histology, and Biochemical Analysis. *Evidence-Based Complementary and Alternative Medicine*.