

Intralesional 5 Fluorouracil For Basal Cell Carcinoma: A Case Review

Dr. Mohak Agarwal¹, Dr. Anushka Rakesh², Dr. Nishtha Malik³, Dr. Kriti Deo⁴, Dr. Ankita Agarwal⁵

1. Third Year Resident, Department of Dermatology, Dr. D. Y. Patil Medical College, Hospital and Research Centre, Dr. D. Y. Patil Vidyapeeth, Pune, Maharashtra, India
2. Third Year Resident, Department of Dermatology, Dr. D. Y. Patil Medical College, Hospital and Research Centre, Dr. D. Y. Patil Vidyapeeth, Pune, Maharashtra, India
3. Second Year Resident, Department of Dermatology, Dr. D. Y. Patil Medical College, Hospital and Research Centre, Dr. D. Y. Patil Vidyapeeth, Pune, Maharashtra, India
4. Professor, Department of Dermatology, Dr. D. Y. Patil Medical College, Hospital and Research Centre, Dr. D. Y. Patil Vidyapeeth, Pune, Maharashtra, India
5. Assistant Professor, Department of Dermatology, Dr. D. Y. Patil Medical College, Hospital and Research Centre, Dr. D. Y. Patil Vidyapeeth, Pune, Maharashtra, India

Corresponding Author:

Dr. Anushka Rakesh Department of Dermatology, Dr. D. Y. Patil Medical College, Hospital and Research Centre, Dr. D. Y. Patil Vidyapeeth, Pune, Maharashtra, India

E-mail: mohakagarwal.doc@gmail.com

DOI: 10.47750/pnr.2022.13.S09.567

Abstract

The most frequent of all non-melanoma skin cancer is basal cell carcinoma (BCC). In descending order of prevalence, the three most frequent BCC forms are nodular, superficial spreading, and penetrating variations. 15–26% of all cases of basal cell carcinoma (BCC) are superficial spreading basal cell carcinomas (SSBCC). However, it can also be noticed on the face. It typically affects the trunk and upper extremities. Excision surgery is the most widely utilized and gold standard treatment for BCC. Intralesional chemotherapeutic drug 5-fluorouracil (5-FU) may be used as adjuvants or alternatives. BCC has modest fatality rates, but because it is so common, it still poses a serious and expensive health burden.

Key words: basal cell carcinoma; 5-fluorouracil; intralesional; management; medical therapy; nonmelanoma skin cancer

Introduction

Intralesional chemotherapy is occasionally used to treat skin cancer, but recent consensus guidelines for the treatment of basal cell carcinoma (BCC) and squamous cell carcinoma (SCC) do not include intralesional chemotherapy.¹

Methotrexate (MTX), 5-fluorouracil (5FU), bleomycin, and interferon solutions are labeled for intravenous or subcutaneous administration. The fact that intralesional use of these agents is not reflected in product labeling may discourage physicians from using them. Similarly, the lack of large well-designed trials or guidelines for the use of intralesional chemotherapy leaves the clinician with little evidence to guide practical management decisions.

Case

A 55-year-old woman with history of occupational acid burn over left side of face presented at the outpatient department (OPD) of Dr. D.Y. Patil Medical College and Hospital with well-defined irregular plaques with hyperpigmentation and peripheral crusting in curvilinear shape extending from left temporal area to left angle of

mandible involving peri aural area of approximate size 8 cm x 6 cm with minimum scarring and atrophy (Figure 1). On palpation it was non tender, indurated with sensation intact.

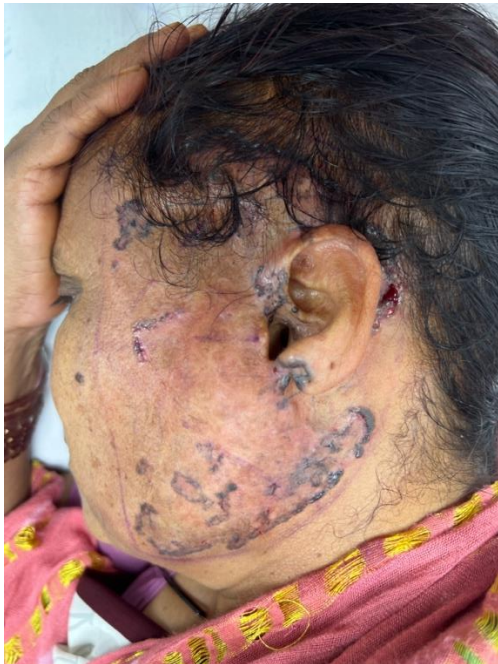

Figure 1: Irregular plaques with hyperpigmentation and peripheral crusting in curvilinear shape

Dermoscopy was done which showed multiple blue-gray dots and globules, arborizing telangiectasia, shiny white blotches and strands and leaf like structure “maple leaf pattern” (Figure 2) which is highly specific for BCC.²⁻⁵

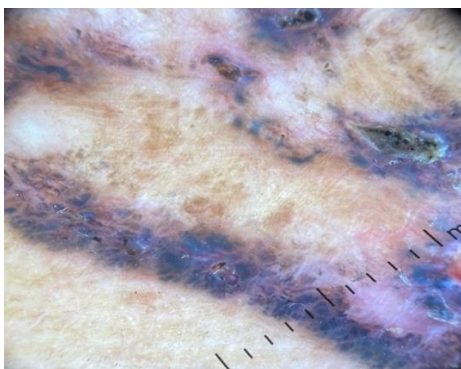


Figure 2: Dermoscopy showed “maple leaf pattern”

A punch biopsy was performed and the histopathology slide showed multiple nests of tumor cells with palisading basaloid cells from the dermo-epidermal junction (Figure 3). Cleft formation was seen between tumor nests and stroma suggestive of retraction artifact. The tumor shows centrally located nuclei, which were crowded with scattered, mitotic figures, and necrotic bodies. The presence of a mucinous stroma distinguished BCC from other basaloid tumors arising from the skin.^{6,7}

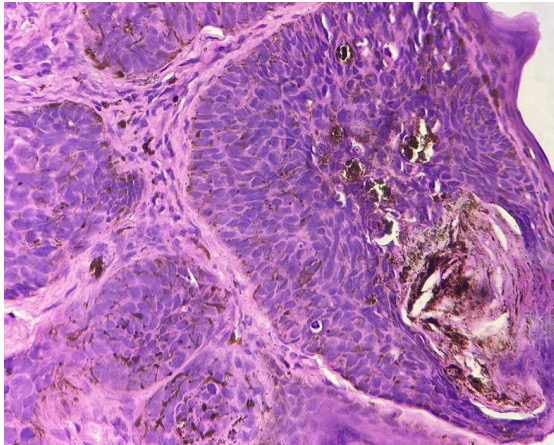


Figure 3: Punch biopsy showed multiple nests of tumor cells with palisading basaloid cells

The diagnosis of superficial pigmented type of BCC was made and patient was counselled for available treatment options. Due to lack of care giver, monetary strain and unwillingness to go for surgery patient was started on intralesional 5-FU therapy.

Treatment

12 sittings of intralesional 5-FU at 50mg/ml were given. The lesion was divided into 4 quadrants (Figure 4). Using 26G insulin needle the chemotherapeutic agent was given over multiple injection site (Figure 5). Local anaesthesia was infiltrated to minimize pain and ice packs were used during procedure to reduce burning and stinging sensation.

The patient was followed up over 12 weeks with progress noted on each visit.

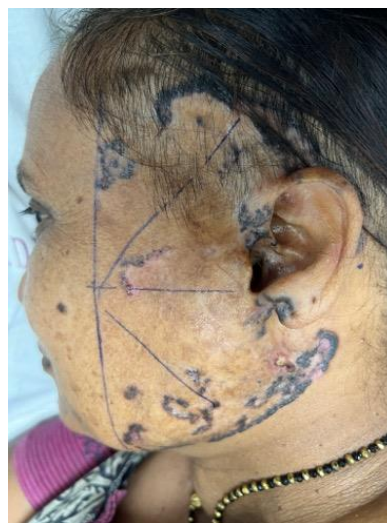

Figure 4: Lesion was divided into 4 quadrants

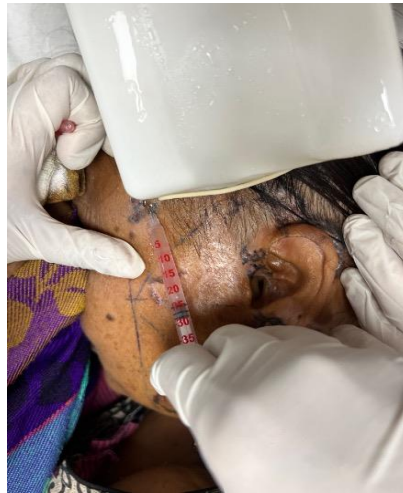

Figure 5: Using 26G insulin needle the chemotherapeutic agent was given over multiple injection site

Result

Following the injection, the lesion showed erythema and patient complained of burning sensation and pain which was relieved in 2-3 days post procedure. At the end of 12 sittings the lesion reduced in size, there was loss of induration and it healed with some atrophy and residual hyperpigmentation. The patient was followed for 5 months with no sign of any new lesion or recurrence.

Discussion

Surgery is still the best way to treat nonmelanoma skin cancer, but for carefully chosen individuals who are unable to have surgery, intralesional chemotherapy is still an option.

BCC represents the majority of tumors treated with any type of intralesional chemotherapy. Interferon alfa-2a, alfa-2b, beta, and gamma⁸⁻¹⁰, 5FU¹¹⁻¹³ and bleomycin^{14,15} have been reported

Tumor dose and frequency of injection vary widely. Some studies used size-based doses; multiple studies used 2 cm² as the threshold to determine if a tumor smaller or larger would receive a lower or higher dose, respectively.¹⁶⁻²⁰ The frequency and number of injections is also not standardized. Some authors followed up the treatment protocol until the tumor became crusted, friable, and/or ulcerated then allowed the area to heal before resuming injections.^{13,21} In general, frequency and number of injections was determined by tumor destruction, reduction in size, or both.

Conclusion

Chemotherapy administered intralesionally (in this case 5-FU) can be a successful and well-tolerated therapeutic option for NMSC. Care must be taken to select amenable tumours, taking into account surgical options, and inform patients of what to expect from the course of treatment, including any potential local or systemic side effects, laboratory monitoring requirements, the requirement for posttreatment biopsies, and clinical follow-up.

Reference

1. Miller SJ, Anderson J, Berg D, Bichakjian CK, Bowen G, Cheney RT, et al. NCCN clinical practice guidelines in oncology. Basal cell and squamous cell skin cancers. Available from: http://www.nccn.org/professionals/physician_gls.
2. Menzies: Dermoscopy of pigmented basal cell carcinoma. Clin. Dermatol. 2002; 20:268-9.
3. Jump up↑ Menzies et al.: Surface microscopy of pigmented basal cell carcinoma. Arch Dermatol 2000; 136:1012-6.
4. Jump up↑ Navarrete-Dechent et al.: Association of Shiny White Blotches and Strands with Nonpigmented Basal Cell Carcinoma: Evaluation of an Additional Dermoscopic Diagnostic Criterion. JAMA Dermatol 2016; 152:546-52.

5. Altamura et al.: Dermatoscopy of basal cell carcinoma: morphologic variability of global and local features and accuracy of diagnosis. *J. Am. Acad. Dermatol.* 2010; 62:67-75.
6. World Health Organization Classification of Tumors. In: LeBoit PE, Burg G, Weedon D, Sarasin A, eds. *Pathology and Genetics of Skin Tumors*. Lyon: IARC Press; 2006. p. 10-33.
7. Mentzel J, Anderegg U, Paasch U, Simon JC, Grupp M, Grunewald S. "Retraction artefacts" in basal cell carcinomas do not result from fixation but likely arise by degradation of extracellular matrix during tumour growth. *J Eur Acad Dermatol Venereol.* 2022;36:e244-7.
8. Kowalzik L, Rogozinski T, Wimheuer R, Pilz J, Manske U, Scholz A, Fierlbeck G, Mohr P, Ochsendorf F, Wagner G, Gaus W, Brzoska J, Jablonska S. Intralesional recombinant interferon beta-1a in the treatment of basal cell carcinoma: results of an open-label multicentre study. *EJD.* 2002, 12(6):558-561
9. Kirby JS, Miller CJ. Intralesional chemotherapy for nonmelanoma skin cancer: a practical review. *J Am Acad Dermatol.* 2010 Oct;63(4):689-702.
10. Tank B, Habets JM, Naafs B, Damsma O, Stolz E, van Joost T. Intralesional treatment of basal cell carcinoma with low-dose recombinant interferon gamma. *J Am Acad Dermatol* 1989;21: 734-5.
11. Edwards L, Whiting D, Rogers D, Luck K, Smiles KA. The effect of intralesional interferon gamma on basal cell carcinomas. *J Am Acad Dermatol* 1990;22:496-500
12. Kurtis B, Rosen T. Treatment of cutaneous neoplasms by intralesional injections of 5-fluorouracil (5-FU). *J Dermatol Surg Oncol* 1980;6:122-7.
13. Kurtis B, Rosen T. Squamous cell carcinoma arising in a basal cell epithelioma treated with 5-fluorouracil. *J Dermatol Surg Oncol* 1979;5:394-6.
14. Avant WH, Huff RC. Intradermal 5-fluorouracil in the treatment of basal cell carcinoma of the face. *South Med J* 1976;69:561-3.
15. Gyurova MS, Stancheva MZ, Arnaudova MN, Yankova RK. Intralesional bleomycin as alternative therapy in the treatment of multiple basal cell carcinomas. *Dermatol Online J* 2006;12:25.
16. Mishima Y, Matunaka M. Effect of bleomycin on benign and malignant cutaneous tumors. *Acta Derm Venereol* 1972;52: 211-5.
17. Dogan B, Harmanyeri Y, Baloglu H, Oztek I. Intralesional alfa-2a interferon therapy for basal cell carcinoma. *Cancer Lett* 1995; 91:215-9. 33. LeGrice P, Baird E, Hodge L. Treatment of basal cell carcinoma with intralesional interferon alpha-2a. *N Z Med J* 1995;108: 206-7.
18. Grob JJ, Collet AM, Munoz MH, Bonerandi JJ. Treatment of large basal-cell carcinomas with intralesional interferon-alpha2a. *Lancet* 1988;1:878-9.
19. Bostanci S, Kocyigit P, Alp A, Erdem C, Gurgey E. Treatment of basal cell carcinoma located in the head and neck region with intralesional interferon a-2a. *Clin Drug Invest* 2005;25:661-7.
20. Chimenti S, Peris K, Di Cristofaro S, Fagnoli MC, Torlone G. Use of recombinant interferon alfa-2b in the treatment of basal cell carcinoma. *Dermatology* 1995;190:214
21. McDonald RR, Georgouras K. Treatment of basal cell carcinoma with intralesional interferon alpha: a case report and literature review. *Australas J Dermatol* 1992;33: 81-6.