

ANTIPHOSPHOLIPID SYNDROME AS A CAUSATIVE FACTOR IN ENDOMETRIAL FAILURE

Akhmadjonova G.M.¹, Negmatshaeva H.N.², Turaeva G.Yu.³

¹ Andijan State Medical Institute, Andijan, Uzbekistan.

DOI: 10.47750/pnr.2022.13.S09.780

Abstract

The article provides data on the results of a morphological study of early post-abortion endometrium women with antiphospholipid syndrome in the early stages of fetal loss up to 8 weeks of gestation in order to identify the causes of reproductive losses in women of the Ferghana Valley. 26 women who received treatment with low molecular weight heparin (LMWH) were analyzed, which made up group 1 and 28 women who received antiplatelet therapy pregravidally, who made up group 2.

Keywords: endometrium, morphology of post-abortion endometrium, abortion, antiphospholipid syndrome.

Introduction

Preservation of reproductive health, ensuring the physiological course of pregnancy and childbirth, the birth of a healthy full-fledged child is among the primary tasks of obstetrics throughout the world and is one of the highest priority areas for healthcare in the Republic of Uzbekistan [1-3,6,16].

Among the problems of modern obstetrics, fetal loss, especially in the early stages, occupies one of the leading places in modern healthcare. Despite the well-known successes achieved in embryology, the frequency of early gestation loss does not have a significant downward trend and, according to various authors, is 5-12% [4,12,13].

Every year, about 10% of losses are born in the world at the preclinical moment of pregnancy diagnosis [5,6,8,10,14].

According to modern concepts, up to 80% of early reproductive losses of unclear etiology are due to immunological disorders, which are usually divided into alloimmune and autoimmune [2,7,11,15,17]. In recent years, the greatest attention of researchers has been drawn to the autoimmune aspects of reproductive losses. One of the representatives of which is the antiphospholipid syndrome.

The purpose of the study:

Analysis of the morphological pattern of early post-abortion endometrium in women with fetal loss before 8 weeks of gestation who received pregravid therapy with identified antiphospholipid syndrome.

Materials and research methods:

For a more in-depth study of the pathogenetic mechanisms of the development of fetal loss in APS, we examined prospectively data on the results of a morphological study of the early post-abortion endometrium of women with antiphospholipid syndrome in the early stages of fetal loss up to 8 weeks of gestation . 26 women who received treatment with low molecular weight heparin (LMWH) were analyzed, which made up group 1 and 28 women who received antiplatelet therapy pregravidally , who made up group 2.

In all women, along with a general clinical examination, strip scrapings of the endometrium were performed immediately after spontaneous miscarriage for morphometric and morphological studies.

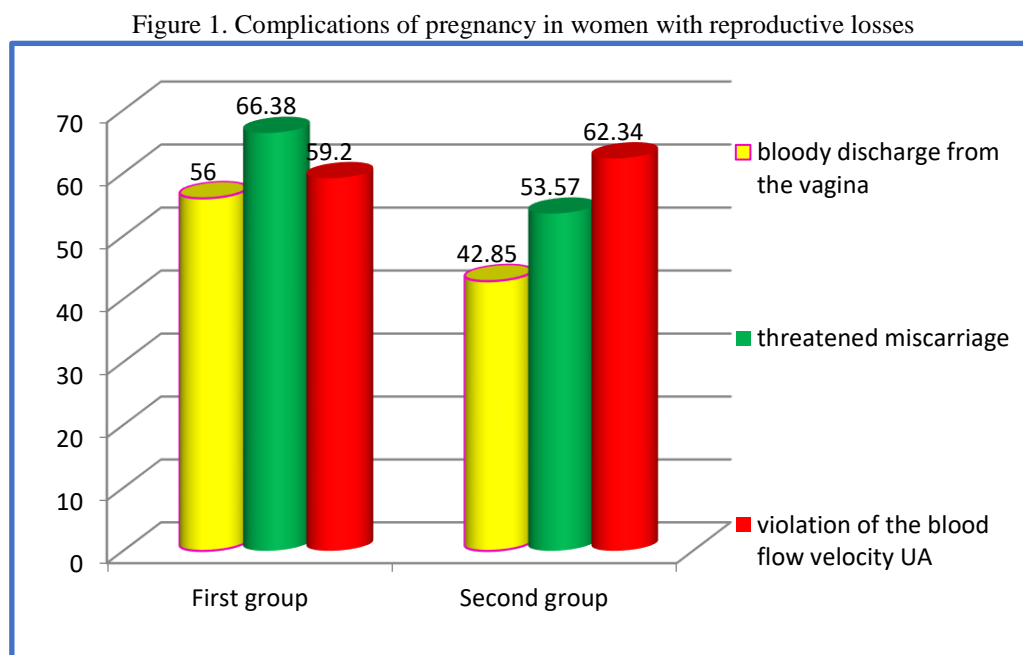
The study was approved by the ethics committee of the ASMI on the ethics of research in humans. Samples were obtained under ultrasound guidance and were available in 30 cases within a gestational age range of 5 to 8 weeks (mean age 7 weeks). Gestational age was estimated from the length of the crown of the fetus. Immediately after removal, the tissues were fixed by immersion for 2 hours in a 4% formalin solution in order to obtain blocks for electron microscopy.

Written consent was obtained from all patients and they were informed about the aims of the study. This study was approved by the committee for the protection of motherhood and childhood of the Andijan State Medical Institute.

Research results

The study of obstetric anamnesis in these groups revealed that the main contingent of the first group had a history of 5 to 7 pregnancy losses, in the second group the same data were revealed.

The most frequent complications of pregnancy in the study groups are bloody discharge from the vagina (56% and 42.85%), the threat of miscarriage (65.38% and 53.57%) and impaired blood flow velocity of the MA (59.2% and 62.34%) already in the early stages (Fig. 1).

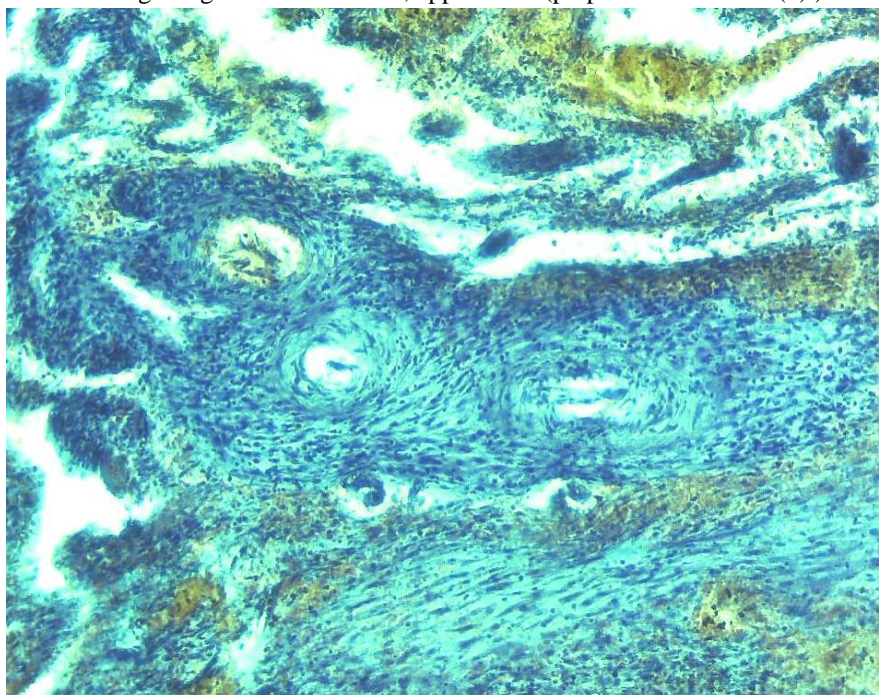


In the earliest available specimen, estimated to be 40–50 days of menstrual age, the pattern showed a superficial layer of the endometrium of a highly secretory nature. The uterine glands were saw-toothed, characteristic of the late secretory phase of the menstrual cycle, and were filled with copious glandular secretions. They were heterogeneous in nature and included a carbohydrate-rich, flaky material interspersed with numerous smooth, round, lipid-like droplets. Although significant differences were observed between the samples, there was a statistically significant negative correlation between the two parameters ($r = -0.74$, $P = 0.02$).

Communication with the intervillous space was traced to a gestational age of at least 8 weeks.

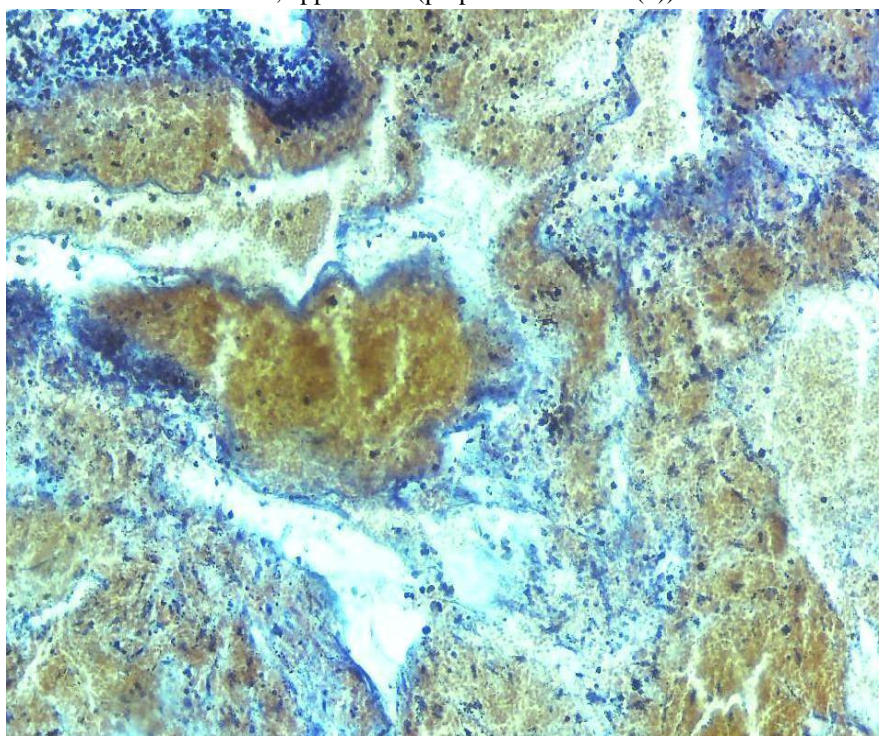
In histological preparations of group 1, the following changes were observed: fibroblastic stromal cells of the endometrium in the stroma of the decidual tissue, in which protein-dystrophic changes (hydropic degeneration, hyaline droplet degeneration), necrobiotic changes, autolysis of some, edema in the stroma, focal and diffuse lymphoid changes and macrophages, hemorrhages, a small number of eosinophils, trophoblasts, chorionic epithelium, venous plethora, hemorrhages, nitibux layer, coagulation necrosis (fibrinoid necrosis) of the chorionic epithelium of anchor varicose veins (Fig. 2).

Fig.2. Condition after abortion and curettage, gestational age 6 weeks. On a micropreparation in the decidual tissue of the stroma, fibroblasts of endometrial stromal cells, in which there are protein-dystrophic changes, edema, infiltration by lymphoid and macrophage cells, venous plethora, hemorrhages. Hematoxylin-eosin staining. Magnification: ob.x10, approx.x10 (preparation 1-2 x 10 (8)).



In the studied group 2, a defective endovascular decidual trophoblastic invasion. Necrobiotic changes in the decidual tissue, edema, fibrinoid necrosis, venous insufficiency, hemorrhages, lymphoid and macrophage cell infiltration.

Fig.3. Condition after abortion and curettage, gestational age 6 weeks. Defective _ endovascular decidual trophoblastic invasion. Necrobiotic changes in decidual tissue. Hematoxylin-eosin staining. Magnification: v.x10, approx.x10 (preparation 1-2x10 (5)).



By 7-8 weeks, endometrial cells in both groups became morphologically more cuboidal in nature with fewer apical protrusions, although significant differences were observed between gland profiles even within the same sample. The apical cell membrane was often covered with long microvilli and short filaments of the rough endoplasmic reticulum were present in the cytoplasm .

In each patient, in parallel, on the 20th day after curettage, the dimensions of the uterus and endometrium were measured in three projections (length, width, and depth) during transvaginal examination. Endometrial volume was calculated as an elongated ellipsoid using the formula: (length X width X depth). The experts performing the ultrasound were highly qualified according to the protocol.

Endometrial thickness (P = 0.02), width (P = 0.002), and volume (P = 0.001) were significantly greater in women receiving anticoagulant therapy (Table 1).

Studies of endometrial regeneration show that the total regeneration time of the postmenstrual re-epithelialization surface is approximately 48-72 hours, which fall on the second and fifth days of the post-abortion period. Since estrogen-dependent changes are not observed until the epithelial surface is restored, it can be assumed that the restoration of the endometrial surface is independent of hormones and results from the stimulation of tissue destruction. This process of regeneration of the endometrial surface has also been observed after spontaneous abortion.

Table I Comparison of indicators of the uterus and endometrium

| Indicator | 1 group | 2 group |
|-------------|-------------|-----------|
| Uterus: | | |
| Length (cm) | 6.75±0.23 | 6.24±0.18 |
| Width (cm) | 4.28 ± 0.17 | 4.08±0.14 |

| | | |
|---------------------------|-------------|----------------|
| Thickness (cm) | 4.23 ± 0.17 | 3.97±0.15 |
| Endometrium: | | |
| Length (cm) | 3.13 ± 0.17 | 3.41±0.21 |
| Width (cm) | 0.81 ± 0.10 | 0.64 ± 0.06* |
| Thickness (cm) | 0.84 ± 0.09 | 0.67 ± 0.06** |
| Volume (cm ³) | 3.85±0.80 | 1.97 ± 0.40*** |

* p = 0.002; **P=0.02; ***P = 0.001.

In contrast to the surface of the endometrium, in women of group 2, the stroma of the endometrium was more vulnerable to scraping. Hormone-dependent rapid stromal proliferation was delayed for 2-3 days after scraping and occurred only on the 10th day after scraping. Moreover, the stroma was usually thinner than expected, and the total volume of endometrial tissue remained subnormal throughout the post-abortion period.

Adequate endometrial thickness appears to be directly related to uterine vascularity, and women with good endometrial thickness on ultrasound but poor intra-endometrial blood flow tend to have a poor reproductive outcome. Uterine perfusion appears to regulate endometrial receptivity, and high uterine resistance to blood flow is associated with recurrent miscarriages. Visualization of the endometrial circulation using three-dimensional Doppler ultrasound shows that the more fetal losses in women's history, the higher the risk of failure of another pregnancy, despite ongoing therapy for antiphospholipid syndrome.

According to our data, the identification of such indicators is possible and are the causes of fetal loss in these groups, which is apparently explained by the development of autosensitization to the therapy, which becomes more complicated with each loss of the fetus.

It has been established that the development of autosensitization to ongoing therapy in women with habitual pregnancy loss is preceded by spontaneous abortions and a history of perinatal losses, despite the use of drugs in the treatment aimed at maintaining pregnancy during previous pregnancies.

Perhaps this fact gives grounds to judge the development of autosensitization in these women, which intensifies with a new unsuccessful attempt to endure pregnancy.

Despite the therapy, this contingent of women had another pregnancy loss already in the early stages. And analyzing the data obtained, it can be assumed that for an uncomplicated course of pregnancy in women with a high history of fetal loss, it seems to be advisable to conduct pregestational therapy over a longer period in order to eliminate the occurrence of autosensitization to the therapy and complete restoration of the reproductive function of the endometrium.

The data obtained, possibly in the future, after a sufficiently deep and complete study, will allow a deeper understanding of the genesis of abortion in sensitized women and optimize the set of measures to prepare for pregnancy and its favorable outcome.

References

1. Maniyozova G.M., Negmatshaeva H.N., Turaeva G.Yu., Asrankulova D.B., Parpieva D.A. On the issue of treatment and prevention of perinatal complications in women with antiphospholipid syndrome // Therapeutic Bulletin of Uzbekistan. -Andijan June 2015. - p.272-276.
2. Maniyozova G.M. Features of the hemostasis system in the dynamics of pregnancy in women with antiphospholipid syndrome // Therapeutic Bulletin of Uzbekistan. -Andijan June 2015. - p.276-279. (14.00.00 №8)

3. Nazhmutdinova D.K., Maniyozova G.M., Turaeva G.Yu., Babich S.M. The content of cytokines in pregnant women with antiphospholipid syndrome // Journal of Theoretical and Clinical Medicine. – Tashkent, 2015 No. 3.-p.85-87.
4. Maniyozova G.M., Babich S.M., Turaeva G.Yu. Doppler parameters in pregnant women with antiphospholipid syndrome against the background of complex treatment with Essentiale Forte N // Journal of Theoretical and Clinical Medicine . – Tashkent, 2015 No. 3.-p.79-82.
5. Maniyozova G., Negmatshaeva H., Yuldasheva O., Turaeva G., Parpieva D. Use of enzymes in complex treatment of antiphospholipid syndrome in women with reproductive losses of andijan state // European medical Heals and Pharmaceutical Journal. – Chechiya , 2014 V7, I2.-pp.1-2.
6. Maniyozova GM, Turaeva G. Yu., Babich SM, Negmatshaeva HN, Mamajanova SA, Abdukaharova S. , Hakimova K. Use of Essentiale Forte N in Complex Treatment of Antiphospholipid Syndrome in Women of Ferghana Valley // Journal of Medical Research and Development . – Germany, Jan. 2015 Vol. 4 Iss . 1, pp. 8-10.
7. Akhmedov F.K. [biochemical markers of preeclampsia development and criteria for early diagnosis](#)- Art of Medicine. International Medical Scientific Journal, 2022. 10.5281/zenodo.6635595.
8. Akhmedov F.K. Features of renal function and some indicators of homeostasis in women with mild preeclampsia// Europen Science Review. - 2015. - №4-5. - C. 58 - 60.
9. F.K. Akhmedov. [The role of interleukin 10 in the development of preeclampsia: diagnosis and prognosis](#)- British Medical Journal, 2022 Volume-2, No 410.5281/zenodo.6912557
10. F.K. Akhmedov., M.N. Negmatullaeva. [The significance of genetic factors and new aspects in predicting preeclampsia \(overview\)](#)- Thematic journal of microbiology, 2021. 10.5281/zenodo.5081885
11. M.N. Negmatulleva., D.I. Tuksanova, M.S Nosirova. [Features of the state of the circulatory system mother and fetus in the second trimester of pregnancy in women with mitral stenosis of rheumatic etiology](#) - European Journal of Biomedical and Pharmaceutical ... , 2020
12. Okada H, Tsuzuki T, Shindoh H, Nishigaki A, Yasuda K, Kanzaki H. Regulation of decidualization and angiogenesis in the human endometrium: mini review. J Obstet Gynaecol Res. 2014; 40: 1180-1187.
13. Evans J, Salomonsen LA, Winship A, et al. Fertile ground: human endometrial programming and lessons in health and disease. Nat Rev Endocrinol . 2016; 12:654-667.
14. Wu D, Kimura F, Zheng L, et al. Chronic endometritis modifies decidualization in human endometrial stromal cells. reproduction Biol Endocrinol . 2017; 15:16.
15. Garrido -Gomez T, Dominguez F, Quinonero A, et al. Defective decidualization during and after severe preeclampsia reveals a possible maternal contribution to the etiology. Proc Natl Acad Science USA. 2017; 114: E8468-E8477.
16. Coulam C. What about superfertility, decidualization , and natural selection? J Assist reproduction Genet . 2016; 33:577-580.
17. Schatz F, Guzeloglu-Kayisli O, Arlier S, Kayisli UA, Lockwood CJ. The role of decidual cells in uterine hemostasis, menstruation, inflammation, adverse pregnancy outcomes and abnormal uterine bleeding. Hum reproduction Update . 2016; 22:497-515.