

INCIDENCE OF MUCOUS RETENTION CYST IN MAXILLARY SINUS; A RETROSPECTIVE RADIOGRAPHIC STUDY

Dr. Archana M Shah¹, Dr. Deshna shah², Dr. Pooja Butoliya³, Dr. Himadri Chakrabarty⁴, Dr. Ila Verma⁵, Dr. Indupriya Chaurasia⁶, Dr. Sugandha Arya⁷

¹Senior lecturer. Dept. of Prosthodontics Crown and Bridge. College faculty of Dental Science, DDU Nadiad.
arhanapray@gmail.com.

²BDS. Illinois state. Deshns. canada@gmail.com.

³Assistant Professor. Dept. of Pediatric and preventive dentistry. Rajasthan dental collage and hospital Jaipur.
Poojabutoliya@gmail.com.

⁴Professor. Dept. of Periodontics. Guru Nanak Institute of Dental Sciences and Research, Kolkata.
radiancedh@rediffmail.com.

⁵Assistant Professor. Dept. of Public health dentistry. Sardar patel post graduate institute of dental and medical sciences. ilaverma1114@gmail.com.

⁶Senior medical officer. Prosthodontics. Nehru Centenary Hospital, Southeastern coal field, Gevra Project.
indupriyachaurasia@gmail.com.

⁷Associate Professor. Dept. of Oral Medicine Radiology. RR Dental College and Hospital. Udaipur.

Corresponding Author: Dr. Sugandha Arya
Email: suggusuggu53@gmail.com

DOI: 10.47750/pnr.2022.13.506.543

Abstract

Mucous retention cysts (MRC) are benign, self-limiting lesions that originate from the accumulation of fluids inside the sinus membrane. MRC are incidental radiological findings and may appear as a round, dome-shaped, relatively radiopaque lesion originating from the wall of the paranasal sinus. Very few studies have investigated the incidence of MRCs in the maxillary sinuses. The present retrospective study evaluated the incidence of MRCs in maxillary sinus.

Results and Conclusion: The prevalence of MRCs was observed to be 2.03 % (61 cases). The mean age of the patients was 35.6 years, and the male: female ratio was 2.5:1. Further studies should be conducted to assess the MRCs location and size in other paranasal sinuses using CT imaging modalities.

Keywords Mucous retention cysts, Orthopantomogram

INTRODUCTION

Mucous retention cysts (MRC) are benign, self-limiting lesions that originate from the accumulation of fluids inside the sinus membrane.^{1,2} Retention cysts of the maxillary sinus arise because of the obstruction of a duct of a seromucinous gland of the sinus mucosa, resulting in cystic dilatation of gland by mucosa or serous fluid.^{3,4} MRC are incidental radiological findings in most cases and are seen in up to 13% of the adult population MRC are classically described as dome-shaped or rounded lesions originating in the maxillary sinus floor mucosa, although they may appear in other locations within the sinus.¹ The size can be variable but the growth is normally slow. The typical radiologic image is a dense, uniform, cupuliform or "rising sun" image, with well defined margins that perfectly respect the underlying bone structures.^{1,3} MRCs generally occur in the maxillary

sinus and are rarely found in the other paranasal sinuses. The incidence of maxillary sinus MRCs in the general population ranges from 1.4% to 9.6%.^{5,6,7} Very few studies have investigated the incidence of MRCs in the maxillary sinuses. The present retrospective study evaluated the incidence of MRCs in maxillary sinus.

MATERIALS AND METHODOLOGY

A retrospective radiographic study was done for a period of 1 year (2021–2022) in the Department of Oral medicine and Radiology at Vyas dental college and Hospital, Jodhpur. In this study after obtaining consent from the patients, a retrospective evaluation of a large patient population data consisting of 3000 Ortho pantomogram views (OPGs) had been performed and archived on the same radiological device (Kodak 8000 C operated at 8-12 mA, peak voltage ranging from 70-80 Kvp).

All OPGs views were screened and evaluated by the corresponding author to estimate the incidence of MRC. The clinical and radiological character in the diagnosis of the disease had been as follows:

1. Most of the mucous retention cysts are clinically asymptomatic and are found in the radiographic view by accident. They are mostly observed as dome-shaped radiopaque lesions on the floor of the maxillary sinus in the radiographic view.
2. Because they originate in the outside of the maxillary bone, the margin of the lesion is not surrounded by the radiopaque line of cortical bone, unlike dentigerous cysts.

The OPGs that did not fulfill the diagnostic criteria or with the ghost images had been excluded.

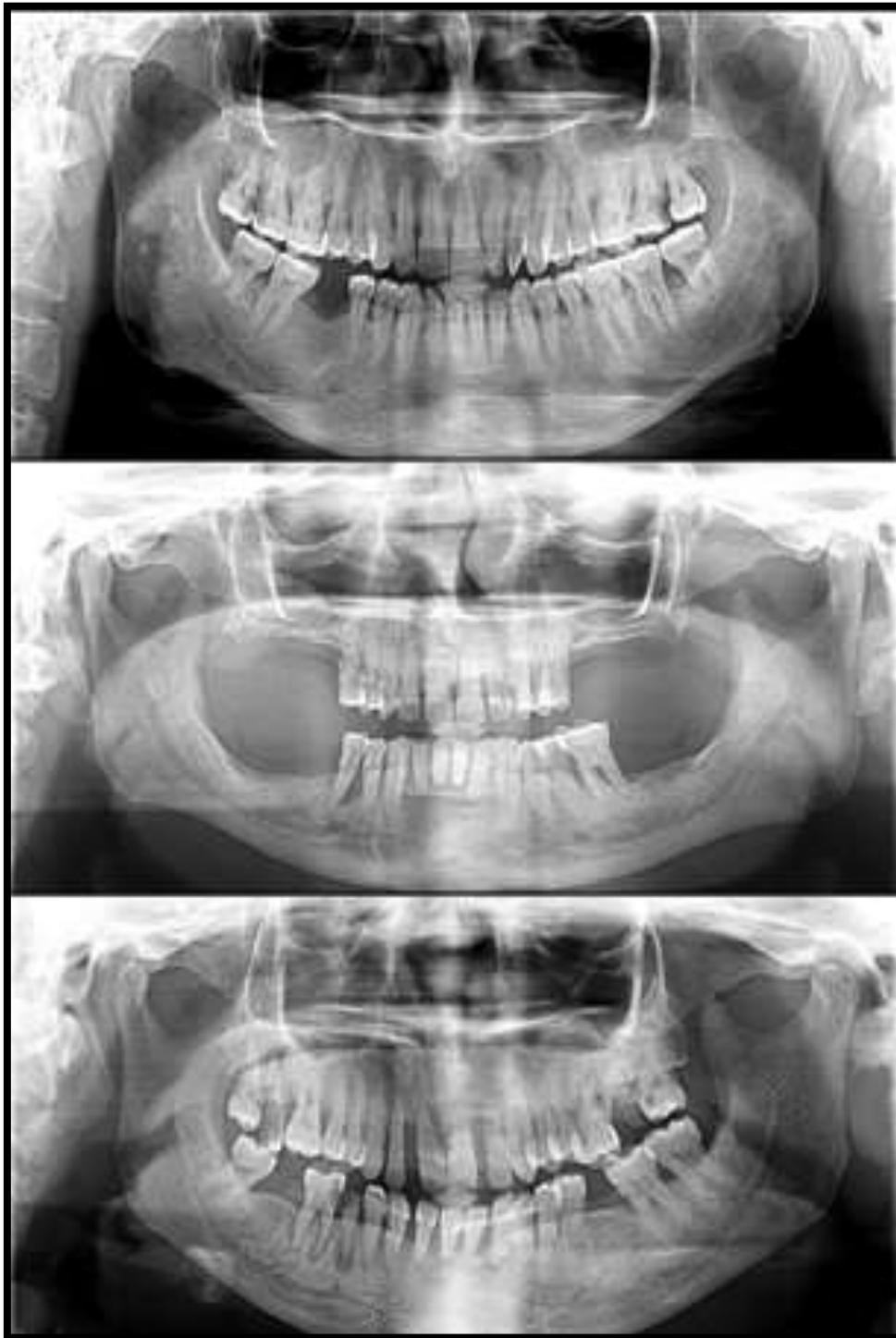
The ethical clearance for the conduct of this research was obtained and no conflicts of interest had been reported in our study.

RESULTS

Amongst the 3000 screened OPG views of patients, a total of 61 fulfilled the diagnostic criteria of MRC thereby, reporting an incidence of 2.03% in Jodhpur population of Western India [Figures 1].

Patients were aged 15–60 years (mean, 35.6 years), with the majority aged 25-40 years. On screening, ratio of MRC affecting the male and female gender group was observed to be (2.5:1). On radiographs, MRCs appeared dome-shaped radiopaque lesions on the floor of the maxillary sinus. In this study OPG radiographic views were sufficient to verify the diagnosis of MRC without the requirement of 3 dimensional staging.

Figures 1 MRCs appearing as dome-shaped radiopaque lesions on the floor of the maxillary sinus in the OPGs.



DISCUSSION

The shape of the maxillary sinus is like a pyramid, and it is connected with the nasal cavity and paranasal sinuses. Therefore, if the physiological status of the maxillary sinus is not normal, the possibility of complications after bone graft, implants can increase.^{8,9} The cyst formed at the maxillary sinus is usually found in the radiographic view by chance, and it is divided into four types: pseudocysts, mucoceles, postoperative maxillary cysts, and MRCs. MRCs may be classified into two types: mucous and serous. MRCs occur frequently and are caused by the obstruction of a seromucinous gland. Serous retention cysts are the result of

fluid accumulation in the submucosal layer. Both types of retention cyst appear as smooth, outwardly convex soft-tissue masses on images.¹⁰ We regarded all retention cysts as MRCs.

Retention cysts have been reported to show a male: female ratio of 2:1, which is supported by our finding of a male:female ratio of 2.5:1. The incidence of MRCs has been reported to be highest among patients aged 30–40 years. Our results were similar to those of Rodrigues et al, showing a prevalence of MRCs in patients aged 25–40 years and a decreased incidence in older adults. Patients were aged 13–57 years (mean, 33.6 years), with the majority aged 20–40 years. The male: female ratio was 1.7:1.

The incidence of retention cysts in the paranasal sinuses is 1.4–9.6% in the general population.^{5,6,7} Allard et al¹¹ reported that the incidence of mucosal sinus cysts was 8.7% in their study of 1,080 patients. The incidence of MRCs in the maxillary sinus has been reported to be between 3.19% and 26%,^{12,13} and we found that the incidence of MRCs was 2.03% in the maxillary sinus in our study of 3000 patients. Studies conducted by Muhlis Bal et al¹⁴ found that the incidence of MRCs was 14.9% in the maxillary sinus, and 15.6% in all paranasal sinuses.

Previous studies have reported predominantly left (60.9% vs. 39.1%) and right (55% vs. 45%) distributions of retention cysts.¹⁵ Muhlis Bal et al¹⁴ observed more left than right paranasal sinus cysts (44.5% vs. 37.4%, respectively) and found that cysts were located most frequently in the maxillary sinuses, followed by the frontal, ethmoid, and sphenoid sinuses. Our study investigated the incidence of MRCs in maxillary sinuses and observed more right (66%) than left (34%) paranasal maxillary sinus.

A differential diagnosis must be done with other benign but more aggressive pathologies such as the nasosinus inverted papilloma, apical radicular cyst, odontogenic tumor, keratocystic, dentigerous cyst, even considering that these injuries can cause intraoral signs and symptoms, with changes in alveolar process. In this region, a variety of cancers may appear; the epidermoid carcinoma seems to be the most common one and should not be confused with the MRCs.¹⁶

CT is the gold standard for radiographic evaluation of the paranasal sinuses; it enables assessment of patency among the intercommunicating channels of the sinuses and allows clinicians to visualise the impact of inflammatory disease and anatomical variations on channel patency.^{14,16} Since, it was a retrospective study and had been aimed to determine solely the incidence of MRCs as an incidental finding in OPG views.

Small lesions may have spontaneous regression; however, the greatest symptomatic cyst and must be removed by surgical treatment, preferably by curettage or maxillary sinusectomy. As time goes by in the absence of any treatment, in 60% of cases the size does not change, 30% decrease or even disappear and only 10% increase in volume.¹⁶ Hence, further studies should be conducted to assess the MRCs location and size in other paranasal sinuses using CT imaging modalities.

CONCLUSION

The prevalence of MRCs was observed to be 2.03 % (61 cases). The mean age of the patients was 35.6 years, and the male: female ratio was 2.5:1. Further studies should be conducted to assess the MRCs location and size in other paranasal sinuses using CT imaging modalities.

REFERENCES

1. Anitua E, Alkhrasat MH, Torre A, Eguia A. Are mucous retention cysts and pseudocysts in the maxillary sinus a risk factor for dental implants? A systematic review. *Med Oral Patol Oral Cir Bucal*. 2020. doi:10.4317/medoral.24155
2. Meer S, Altini M. Cysts and pseudocysts of the maxillary antrum revisited. *SADJ*. 2006;61:10-3.
3. Giotakis EI, Weber RK. Cysts of the maxillary sinus: a literature review. *Int Forum Allergy Rhinol*. 2013;3:766-71.
4. Kim SB, Yun PY, Kim YK. Clinical evaluation of sinus bone graft in patients with mucous retention cyst. *Maxillofac Plast Reconstr Surg*. 2016;38:35.
5. Sievers KW, Greess H, Baum U, Dobritz M, Lenz M. Paranasal sinuses and nasopharynx CT and MRI *Eur J Radiol* 2000;33: 185-202.

6. Anon JB. Report of the rhinosinusitis task force committee meeting. *Otolaryngol. Head Neck* 1997;Surg Suppl 117: S1-68.
7. Bósio JA, Tanaka O, Rovigatti E, Gruner SK. The incidence of maxillary sinus retention cysts in orthodontic patients. *World J Orthod* 2009;10: e7-e8.
8. Beaumont C, Zafirooulos GG, Rohmann K. Prevalence of maxillary sinus disease and abnormalities in patients scheduled for sinus lift procedures. *J Periodontol* 2005;76:461-74.
9. Misch CM, Misch CE, Resnik RR. Post-operative maxillary cyst associated with a maxillary sinus elevation procedure: a case report. *J Oral Implantol* 1991;17:432-7.
10. Seong-Beom Kim, Pil-Young Yun and Young-Kyun Kim. Clinical evaluation of sinus bone graft in patients with mucous retention cyst. *Maxillofacial Plastic and Reconstructive Surgery* 2016;38:35.
11. Allard RHB, van der Kwast WAM, van der Waal I. Mucosal antral cysts. Review of the literature and report of a radiographic survey. *Oral Surg Oral Med Oral Pathol* 1981;51: 2-9.
12. Bhattacharyya N. Do maxillary sinus retention cysts reflect obstructive sinus phenomena? *Arch Otolaryngol Head Neck Surg* 2000;126: 1369-1371.
13. Coleman H, Meer S, Altini M, Reyneke J, Becker P. Maxillary sinus pathology in 119 patients—a histopathologic study *SADJ* 2005;60: 140,142-145.
14. Muhlis Ba et al. Mucous Retention Cysts in the Paranasal Sinuses: A Retrospective Study. *Otolaryngology online* 2016; 6 (2): 109.
15. Casamassimo PS, Lilly GE. Mucosal cysts of the maxillary sinus: a clinical and radiographic study. *Oral Surg Oral Med Oral Pathol* 1980; 50: 282-286.
16. Gonçalves et al. Symptomatic mucous retention cysts of the maxillary sinus: case report. *RSBO*. 2015;Apr-Jun;12(2):233-7