

A Rare Case Of Covid 19 Presenting As Generalized Tonic Clonic Seizures

Aditi Patel¹, Varsha Bhatt², Pranav Jawade³, Anusha Vattikutti⁴, Subhashini Vadvel⁵

¹Junior resident, Department of General Medicine, Dr. DY Patil Hospital and Research Centre, Dr. DY Patil Vidyapeeth, Pimpri, Pune. 411018, Maharashtra, India

²Professor, Dept of Medicine, Dr D.Y. Patil Medical College Hospital and Research Center Dr. DY Patil Vidyapeeth, Pimpri, Pune 411018, Maharashtra, India

³Junior resident, Department of General Medicine, Dr. DY Patil Hospital and Research Centre, Dr. DY Patil Vidyapeeth, Pimpri, Pune. 411018, Maharashtra, India

⁴Junior resident, Department of General Medicine, Dr. DY Patil Hospital and Research Centre, Dr. DY Patil Vidyapeeth, Pimpri, Pune. 411018, Maharashtra, India

⁵Junior resident, Department of General Medicine, Dr. DY Patil Hospital and Research Centre, Dr. DY Patil Vidyapeeth, Pimpri, Pune. 411018, Maharashtra, India

Corresponding author: Dr. Aditi Patel,
Junior resident, Department of General Medicine
Dr. DY Patil Hospital and Research Centre,
Dr. DY Patil Vidyapeeth, Pimpri, Pune.
Email ID: aditibmrcycle4@gmail.com,
DOI: 10.47750/pnr.2023.14.502.05

Abstract

Introduction: Coronavirus disease 2019 (COVID-19) is a novel coronavirus that was frequently isolated from Wuhan, China in patients with respiratory tract infections. The most prevalent symptoms are fever and respiratory tract involvement. In this paper, seizures, an uncommon manifestation of the condition, is described.

Case Discussion: A previously healthy 34-year-old female was taken to the emergency room with a widespread tonic-clonic seizure. Five days prior to admission, the patient complained of fever, cough, headache, widespread weakness, and myalgias. She experienced two episodes of convulsions around one hour ago. The MRI of the brain was normal, whereas the CT of the chest indicated localised ground-glass opacities. Using real-time PCR, the respiratory material was positive for COVID-19. The patient's symptoms improved after using anticonvulsive and antiviral drugs.

Conclusions: To our knowledge, this is one of the rare case studies reporting a link between frequent seizures and COVID-19.

Keywords: Seizure, COVID-19, Novel Coronavirus, Case Report, Convulsion

INTRODUCTION:

On December 31, 2019, in Wuhan, Hubei, China, a novel coronavirus designated Coronavirus Disease 2019 (COVID-19) was isolated from individuals who seemed to have respiratory tract infections of unclear origin. The symptoms of the infected patients ranged from mild to severe: Fever (98% of patients), cough (76%), dyspnea (55%), myalgia (55%) and weariness (44% of patients) are the most frequent complaints.¹ According to some pieces of data, COVID-19 caused acute renal injury, acute heart injury, and gastrointestinal involvement. Patients with COVID-19 have neurological symptoms, according to Mao et al.² Headache, hypogeusia, hyposmia, and dizziness were the most prevalent symptoms. Severe patients had ischemic or hemorrhagic stroke, and loss of consciousness.² At this point, patients with fever and/or respiratory symptoms who had close contact with a confirmed or suspected COVID-19 patient should be given the greatest consideration. To the best of our knowledge, COVID-19 has rarely been linked to any seizures. In this report, we present a patient who experienced numerous seizures for the first time, most likely as a result of COVID-19.

CASE REPORT:

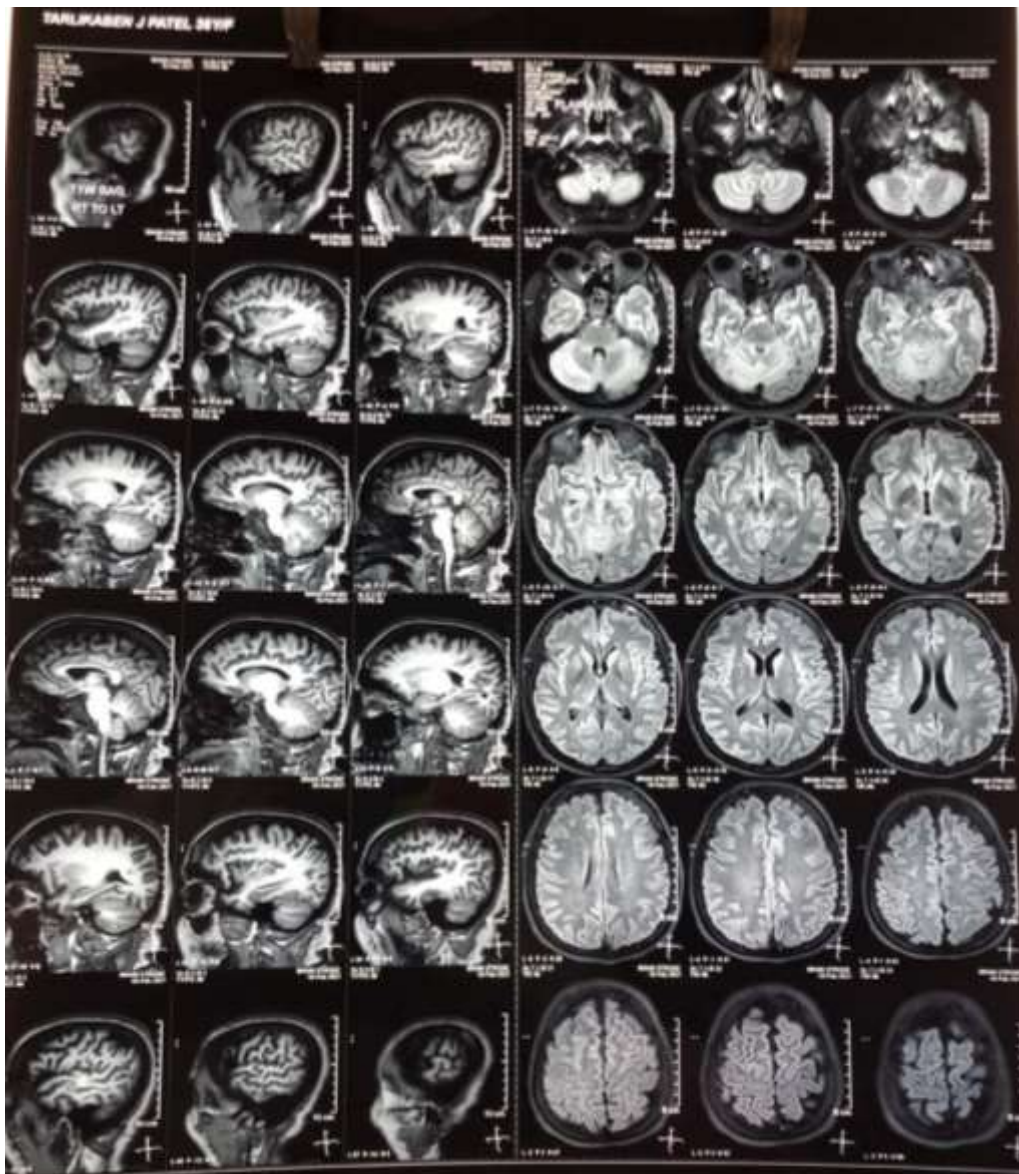
A previously healthy 30-year-old female was admitted to the emergency department with a history of widespread tonic-clonic seizure one hour ago. The patient lacked a history of alcohol or any substance abuse. She has had a cough with expectoration consisting of white, scanty mucoid discharge for five days before presenting for admission. She also experienced fever (axillary T = 39°C) which was associated with chills and rigors along with headache, generalized weakness and myalgias since last 7 days prior to admission. The patient's first generalised tonic-clonic (GTC) seizure occurred one hour prior to admission. Then, one more seizure occurred immediately upon admission which was an hour later from the previous episode. The patient remained tired and confused for thirty minutes to one hour following the last seizure. The patient was conscious between the attacks. She had neither an epileptic seizure history nor a family history of seizure disorders. At the time of hospitalisation in the Emergency Department, the body temperature was 38.6 °C, the blood pressure was 120/70 mmHg, the heart rate was 90 beats per minute, and the oxygen saturation in the air was 90 % on room air and she was kept on 2 litres of oxygen delivered via nasal prongs. The patient was intermittently drowsy and disoriented. Pupils were midsize and reactive to light and accommodation. There was no papilloedema in fundus evaluation. The patient was able to move all four limbs, and neither a stiff neck nor nuchal stiffness was present. Deep tendon reflexes were normal. Cranial nerves were intact on examination. There was no involuntary bowel or bladder involvement. No skin rash was noticed, and all other systems, including the cardiovascular and abdominal examinations, were normal. Initial laboratory examinations revealed normal blood glucose, electrolytes, calcium, phosphorus, magnesium, liver function test, urea, and creatinine levels. The routine laboratory blood parameters were as follows: haemoglobin 7.6 g %, white blood cell count of 4200 cells per microliter with 24% lymphocytes and 60% neutrophils, elevated erythrocyte sedimentation rate (ESR = 45 mm/hour) and C-reactive protein (CRP) levels - 56 mg/dl. Renal and Liver function tests were normal. The cerebrospinal fluid (CSF) from the lumbar puncture was normal. No bacterial growth was observed after 48 hours of incubation in the culture. The MRI of the brain with angiography was done which was normal. Due to the patient's cough and fever, a chest CT was performed and revealed focused ground-glass opacities with CORADS 5 and CT severity score of 18. (Figure 1). RT PCR for nasal and pharyngeal swabs, and CSF for COVID-19 were sent. COVID-19 was detected in nasal and pharyngeal samples. Injectable steroids and Remdesivir were started. Vancomycin and ceftriaxone were also started. The CSF sample showed no evidence of COVID-19 infection. Injection Lorazepam and Leviteracetam was given

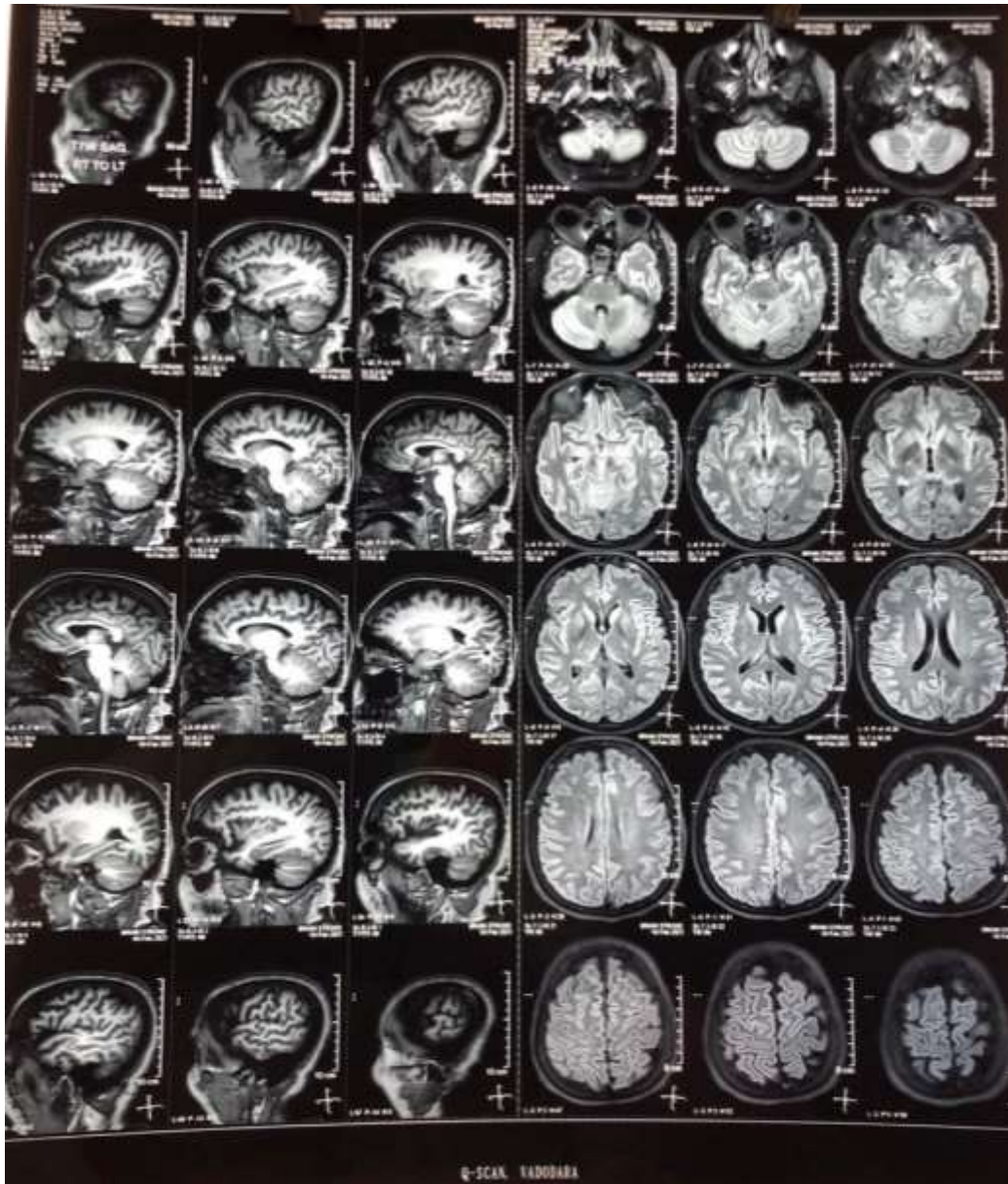
Patient remained unconscious with further drop in saturation. Patient went into status epilepticus and was electively intubated for airway protection and possibility of giving sedative infusion which may cause further respiratory depression. Injection lacosamide was also added. CSF biofire was sent, which was normal. CSF RT PCR COVID was also sent, which was negative. The patient was observed further for seven days. The patient's fever and seizures were under control and the oxygen requirement was decreasing and she was subsequently

extubated. She was kept for a period of observation for a period of 7 more days in the ward and anti epileptics were shifted to oral forms and was later discharged.

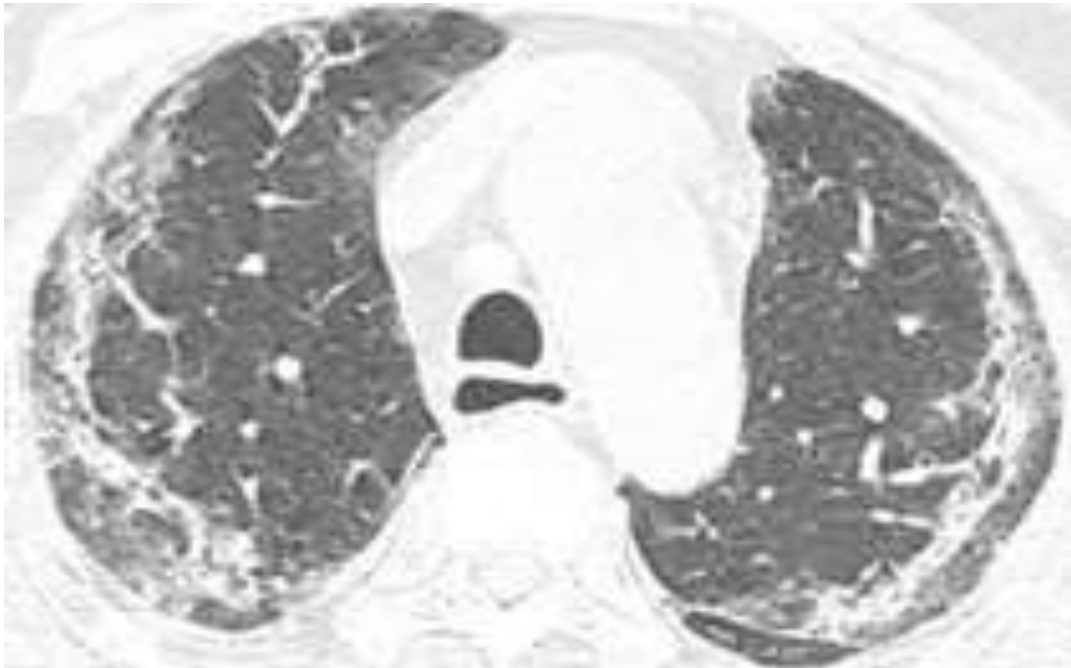

Figure 1 :HRCT showing peripheral ground glass opacities.





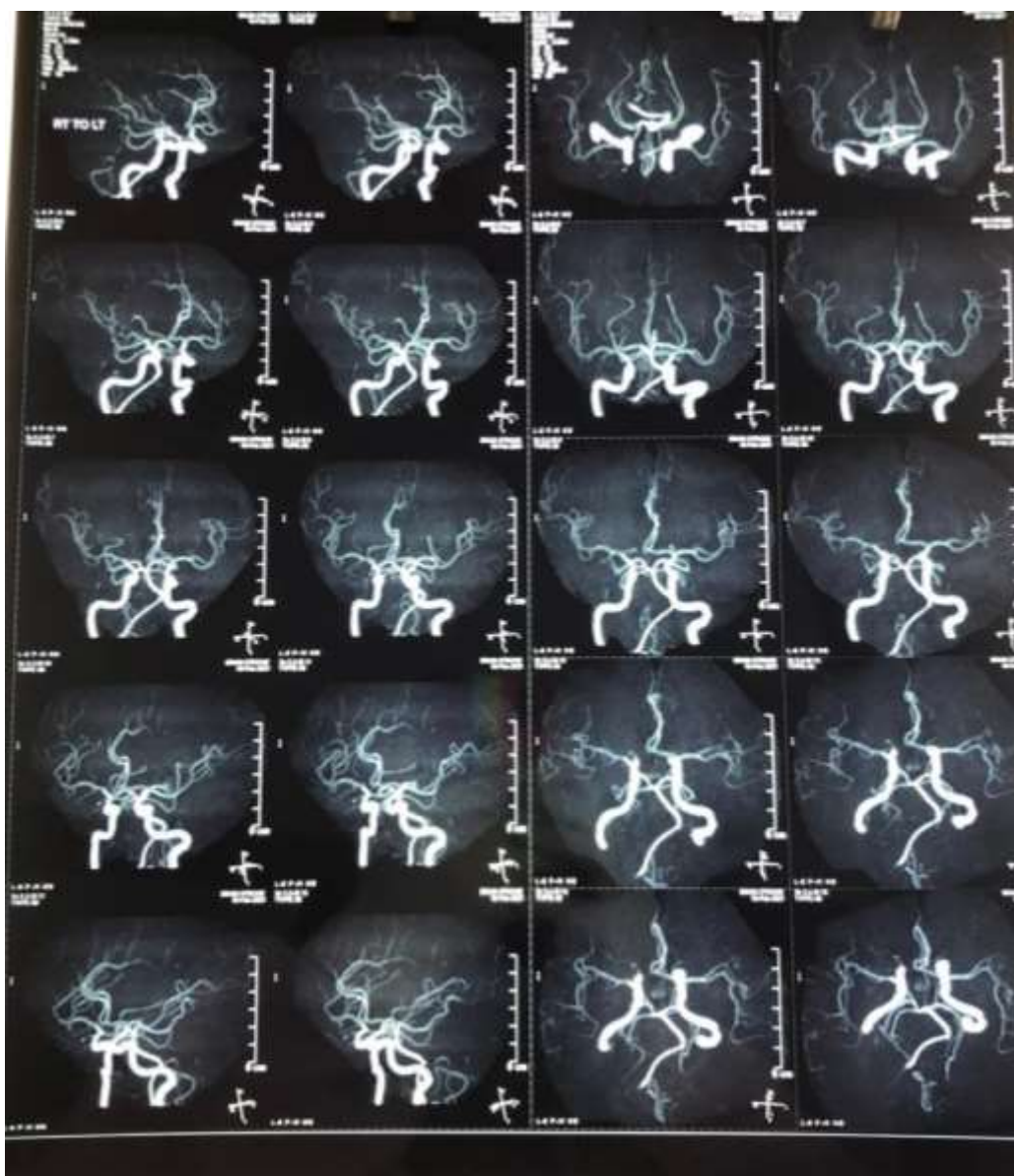


Figure 2: MRI of Brain and Angiography which was normal.

DISCUSSION:

One of the most prevalent viruses that predominantly affects the respiratory system of humans is called the coronavirus. The severe acute respiratory syndrome (SARS) in 2002 and the Middle East respiratory syndrome (MERS) in 2012 were both caused by outbreaks of coronaviruses that occurred in the past. SARS-CoV2 is the virus that caused the most recent pandemic of coronavirus infection, which is known as coronavirus disease (COVID-19). This virus is the agent that causes an illness that has the potential to be fatal.² After an incubation period of around five days, COVID-19 infection will manifest itself with its characteristic symptoms. Fever, cough, and exhaustion are the symptoms of COVID-19 infection that are most frequently seen at the beginning of the disease. Other symptoms include production of sputum, headache, hemoptysis, diarrhoea, and dyspnea. Patients who have severe forms of the condition may suffer severe pneumonia, acute respiratory distress syndrome, organ failure, and abrupt heart damage.³ Coronavirus causes inflammation and demyelination when it enters the central nervous system (CNS) through the olfactory bulb after being spread through the nasal passages during an infection. In fewer than seven days after the infection has taken hold, the virus has the potential to spread throughout the entire brain as well as the cerebrospinal fluid (CSF).⁴ Patients who have an infection caused by a

coronavirus may experience a variety of neurological symptoms, such as febrile seizures, convulsions, a change in mental status, encephalomyelitis, and encephalitis. ⁴ Moriguchi et al. were the first people to document the occurrence of seizures in COVID 19 patients. ⁵ Mao et al. described the neurological manifestations that people infected with COVID-19 can experience. ² Headaches and vertigo were the symptoms that people reported experiencing the most frequently. ² In this report, we described a patient who suffered with COVID-19 along with recurrent seizures and had no prior history of any medical conditions. It is possible that the seizure was brought on by a primary infection or by the reactivation of a dormant virus that had been present. In patients who have viral infections, the aetiology of seizures can be caused by a number of different processes, such as the virus's direct penetration of brain tissue and creation of toxins, or the brain's own production of inflammatory mediators. ⁶ According to the findings of Huang et al., COVID-19 activates the inflammatory cascade and, as a consequence, causes the production of inflammatory cytokines. These cytokines include the interleukins 2, 6, 7, and 10, as well as the tumour necrotizing factor and the granulocyte colony-stimulating factor. ⁷ According to research done in the past, the primary agents responsible for boosting the immune system include the cytokines TNF- and IL-6, as well as C3 from the complement system. Following one another, these cytokines can activate glutamate receptors, which in turn can induce hyperexcitability in the neuronal circuitry and contribute to the development of abrupt seizures. ^{8,9,10}

CONCLUSION:

This is one of the rare case studies that, to our knowledge, reports a connection between seizures and COVID-19. According to our opinion, encephalitis and the virus's invasion of the brain, as well as the potentially harmful effects of inflammatory cytokines, may be the cause of seizures. COVID-19 can result in neurological symptoms like the start of seizures and a hypervigilant state. Testing for the SARS COV-2 virus should be done on patients who have new-onset seizures and impaired mental status in addition to the typical clinical symptoms of COVID-19.

Conflict of interest: All authors declare no COI

Ethics: There is no ethical violation as it is based on voluntary anonymous interviews

Funding: No external funding

Guarantor: Dr. Aditi Patel will act as guarantor of this article on behalf of all authors

Acknowledgements: Nil

REFERENCES;

1. Karimi N, Razavi AS, Rouhani N. Frequent convulsive seizures in an adult patient with COVID-19: a case report. *Iranian Red Crescent Medical Journal*. 2020 Mar 27;22(3).
2. Mao L, Wang M, Chen S, He Q, Chang J, Hong C, Zhou Y, Wang D, Li Y, Jin H, Hu B. Neurological manifestations of hospitalized patients with COVID-19 in Wuhan, China: a retrospective case series study. *MedRxiv*. 2020 Jan 1.
3. Rothan HA, Byrareddy SN. The epidemiology and pathogenesis of coronavirus disease (COVID-19) outbreak. *Journal of autoimmunity*. 2020 May 1;109:102433.
4. Bohmwald K, Gálvez NM, Ríos M, Kalergis AM. Neurologic alterations due to respiratory virus infections. *Frontiers in cellular neuroscience*. 2018 Oct 26;12:386.
5. Moriguchi T, Harii N, Goto J, Harada D, Sugawara H, Takamino J, Ueno M, Sakata H, Kondo K, Myose N, Nakao A. A first case of meningitis/encephalitis associated with SARS-Coronavirus-2. *International journal of infectious diseases*. 2020 May 1;94:55-8.
6. Libbey JE, Fujinami RS. Neurotropic viral infections leading to epilepsy: Focus on Theiler's murine encephalomyelitis virus. *Future Virol*. 2011;6(11):1339-50.
7. Huang C, Wang Y, Li X, Ren L, Zhao J, Hu Y, et al. Clinical features of patients infected with 2019 novel coronavirus in Wuhan, China. *Lancet*. 2020;395(10223):497-506
8. Singhi P. Infectious causes of seizures and epilepsy in the developing world. *Dev Med Child Neurol*. 2011;53(7):600-9.
9. Libbey JE, Kennett NJ, Wilcox KS, White HS, Fujinami RS. Interleukin-6, produced by resident cells of the central nervous system and infiltrating cells, contributes to the development of seizures following viral infection. *J Virol*. 2011;85(14):6913-22.
10. Libbey JE, Kirkman NJ, Smith MC, Tanaka T, Wilcox KS, White HS, et al. Seizures following picornavirus infection. *Epilepsia*. 2008;49(6):1066-74.