

# A Critical Review on Changing Epidemiology of Human Monkeypox-A Current Threat with Multi-Country Outbreak

Anubhav Dubey<sup>1</sup>, Raghuvendra Singh<sup>2</sup>, Ashish Kumar<sup>2</sup>, Gaurav Mishra<sup>4</sup>, Anubha Gupta<sup>5</sup>, Anuj Sonker<sup>5</sup>, Dr. Amit Mishra<sup>6</sup>

<sup>1</sup>Assistant Professor, Department of Pharmacology, Maharana Pratap College of Pharmacy, Kanpur Uttar Pradesh, India.

<sup>2</sup>Research Scholar, Department of Pharmacy, Career Point University, Kota, Rajasthan, India.

<sup>4</sup>Lecturer, Department of Pharmacy, Shri Ramdevi Ramdayal Tripathi Mahila Polytechnic, Saket Nagar, Kanpur Uttar Pradesh, India.

<sup>5</sup>Assistant Professor, Department of Pharmacy, Maharana Pratap College of Pharmaceutical Sciences, Kanpur Uttar Pradesh, India.

<sup>6</sup>Professor, Department of Pharmaceutics, Maharana Pratap College of Pharmaceutical Sciences, Kanpur Uttar Pradesh, India.

Email: anubhavdwivedi803@gmail.com

DOI: 10.47750/pnr.2022.13.S01.82

## Abstract

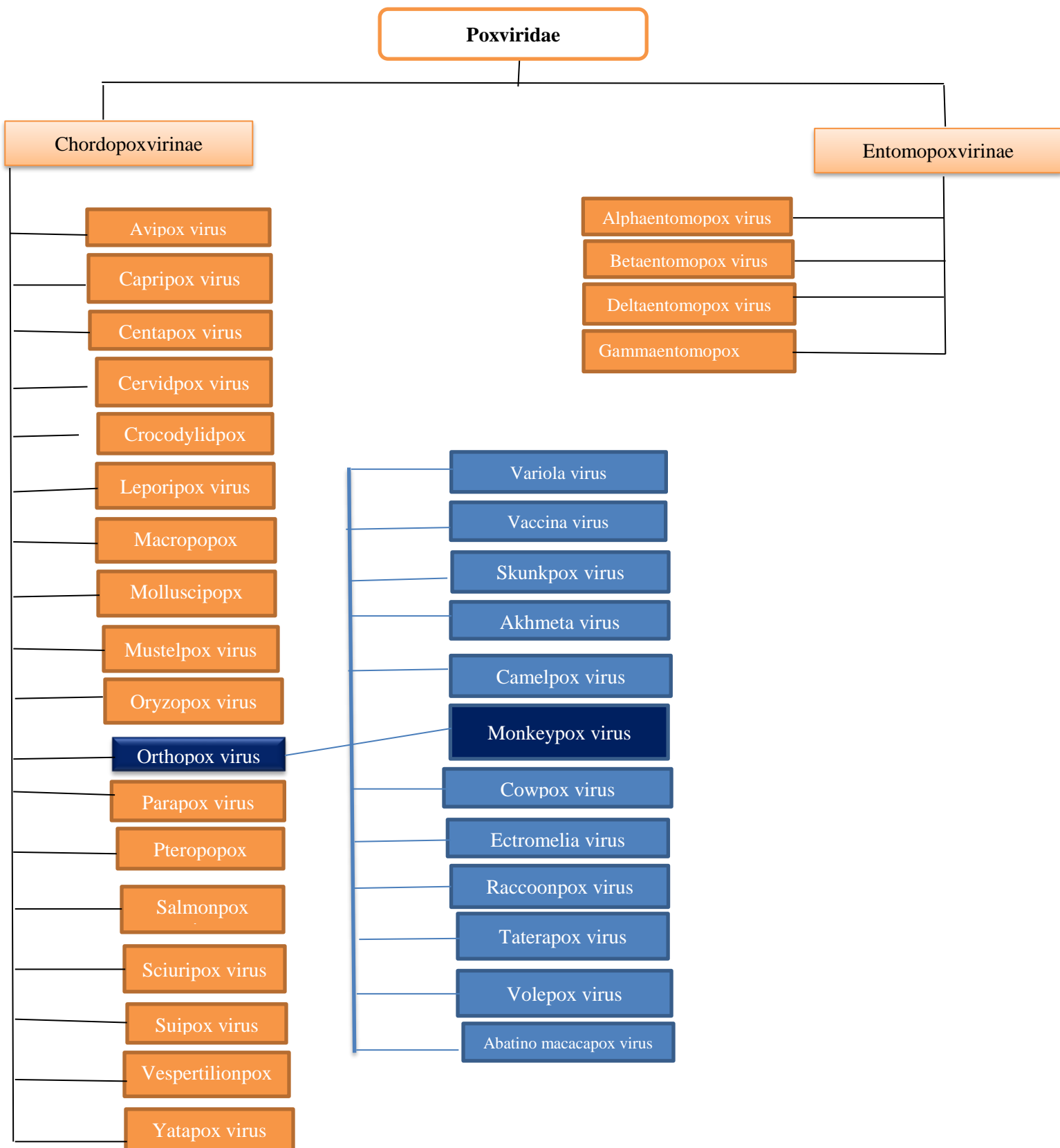
As concerns about the 2019 coronavirus disease (COVID-19) epidemic begin to dissipate, nations around the world are instead focusing on the outbreak of monkeypox in some areas. Once restricted to specific areas of Africa, the 2022 pandemic has primarily affected European countries and the rest of the western hemisphere. Although numerous groups are working on contact-tracing initiatives, the original cause of this epidemic remains a mystery. The monkeypox virus is a member of the Poxviridae family, which includes many other zoonotic viruses. After smallpox was eradicated worldwide, occurrences of monkeypox gained international attention in the 1970s. Cross-immunity against monkeypox was achieved through the use of the smallpox vaccine. A rise in the incidence of monkeypox followed the end of routine vaccination against smallpox. An outbreak in the United States in 2003 brought monkeypox to the forefront of public consciousness. Although it has been given the moniker "monkeypox," this particular virus did not initially manifest in these small mammals. To this day, the real origin of monkeypox remains a mystery, however it has been speculated that various rodents and tiny mammals are the carriers of the virus. The virus that causes monkeypox was originally observed in macaque monkeys, hence the name. Monkeypox is seldom spread from person to person, but when it does, it's usually through a person's mucocutaneous lesions or through airborne droplets. Although there is no successful treatment for those who have contracted the virus at this time, complimentary treatments can be given to alleviate symptoms; medications such as tecovirimat may be given to those with extremely severe infections. There are no universally accepted standards for administering these medicines, making their efficacy open to debate.

**Keywords:** Monkeypox virus, Poxviridae family, Cross-immunity, COVID-19, Mammals.

## INTRODUCTION

Significant international interest [1, 2] was sparked by the 2022 monkeypox epidemic that affected numerous nations in both endemic and nonendemic regions. Monkeypox virus, a once-ignored zoonotic virus endemic to West and Central Africa, was first detected in 1958 [3] in nonhuman monkeys maintained for research in Denmark. The very first-person case was documented in 1970 in the Democratic Republic of the Congo [4]. Spreading like wildfire over Africa over the previous half-century, several thousand human cases have been documented so far. A few instances and localised epidemics have been reported in regions where the virus is not naturally found [5]. Monkeypox virus and other zoonotic pox-viruses' potential to spread and take over the ecological niche previously inhabited by the closely related variola virus [6, 7] has been a theoretical concern for quite some time. It has become increasingly likely in the last 20 years [6-8] due to the combined consequences of deforestation, population expansion, encroachment on animal reservoir habitats, growing human travel, and strengthened global interconnectedness. As the number of confirmed cases rises, it is crucial that practitioners everywhere refresh their memories on this zoonotic infection and its prevention, clinical care, prophylaxis, and the fundamentals of infection control. With this review, we hope to give healthcare providers with a foundational understanding of monkeypox virus infection before they meet it in the course of their work.

## VIROLOGY

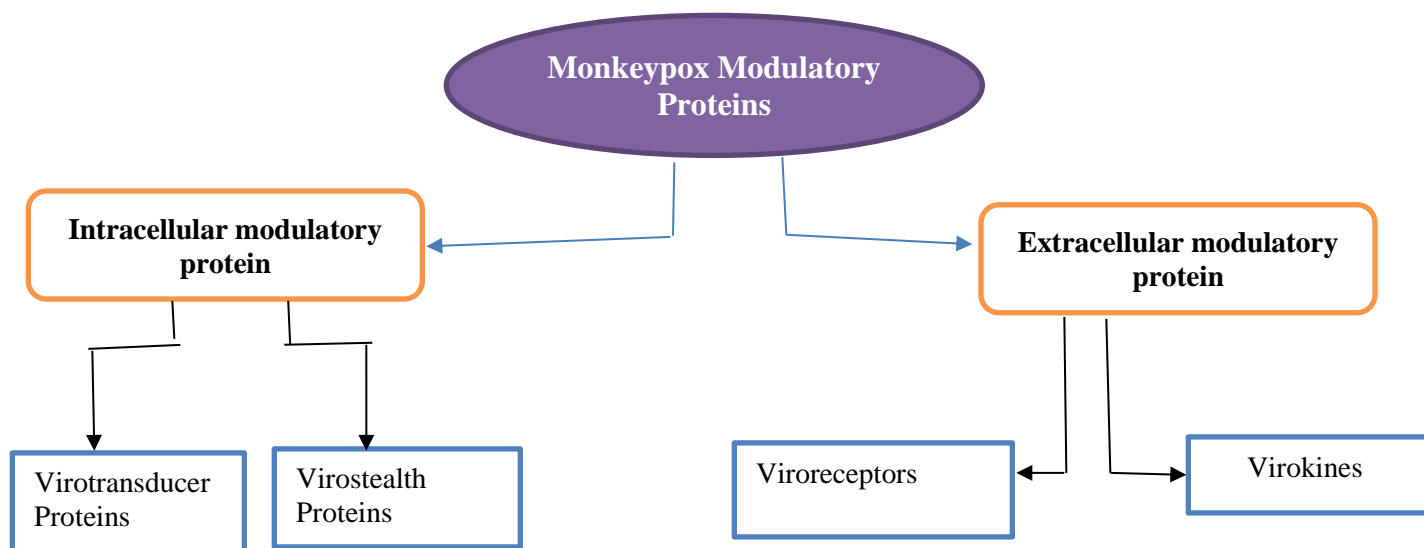


**FIGURE 1:** Taxonomy and Classification of Monkeypox

Many different species, including birds, reptiles, insects, and mammals, can become infected by viruses belonging to the Poxviridae family, which are composed of double-stranded deoxyribonucleic acid. Chordopoxvirinae (consisting of 18 genera

and 52 species) and Entomopoxvirinae are the two subfamilies that make up this family (with 4 genera and 30 species). Monkeypox is caused by a member of the genus Orthopoxvirus of the family Poxviridae, subfamily Chordopoxvirinae [9,11]. Numerous poxviruses, such as Variola (smallpox), Cowpox, Monkeypox, Vaccinia, Camelpox, Alaskapox, Yaba monkey tumor virus, Tanapox virus, Orf virus, Pseudocowpox virus, Bovine papular stomatitis virus, Buffalopox, and Molluscum contagiosum, have been linked to human diseases. Both the variola virus and the molluscum contagiosum virus rely on humans as a reservoir host [10]. Due to its adaptability, monkeypox virus (MPXV) has been able to persist in the wild for a long period and occasionally infect humans through spillover episodes [9]. Additionally, infection with any member of the genus gives some protection against infection with any other members of the same genus (OPXV) [12, 13]. The genome of an orthopoxvirus is around 200-500 kbp [14] and codes for more than 200 genes; these viruses are big (size range: 140-450 nm) and have a brick-like shape. Many of the genes encoded by the OPXV genome are likely to play important roles in the host antiviral response but are not required for virus replication in cell culture. In the cytoplasm of infected cells, poxviruses follow intricate molecular pathways to complete their reproduction cycle [10, 15]. Vaccinia virus, utilised to create the vaccine that contributed to the global eradication of smallpox, has a well-characterized intracellular replication cycle; fundamental characteristics of this replication cycle are comparable for all poxviruses [15]. The infection cycle can be kicked off by either the surface glycoprotein-expressing mature intracellular virion or the surface glycoprotein-expressing external wrapped virion. Although not all cellular receptors have been thoroughly defined [16], it is widely believed that glycosaminoglycans, which are found on the surface of all mammalian cells, play a critical role in the binding of the virion to the cell membrane. The scope of this analysis does not provide a comprehensive description of the replication cycle, which has been reported elsewhere [18,19]. It is believed that millions of people died from smallpox [17] all over the world, making it one of the worst infectious diseases in human history. The devastating effects of smallpox serve as a reminder that OPXV may be extremely dangerous infections. Despite the fact that smallpox's genesis is a mystery, there is some evidence that the Variola virus developed from an ancient rodent poxvirus many centuries ago [22]. It has long been recognised [20,21] that zoonotic OPXV infections like MPXV pose an ever-increasing threat. The worldwide smallpox immunisation programme was discontinued more than 40 years ago, leaving a sizable segment of the population without protection against the disease and the zoonotic variant of OPV. All of this suggests that MPXV, like other zoonotic orthopoxviruses, might develop the potential to more easily transmit between people and produce greater outbreaks under the correct conditions, such as rising human infection rates and prolonged absence of vaccination immunity [23].

Proteins that have immunosuppressive effects on the host can be divided into two classes, those that operate intracellularly and those that act extracellularly. As shown in Figure 2, there are two main classes of proteins that perform modulatory activities against the host immune response. Proteins found inside of cells include both virotransducer proteins and virostealth proteins. By inhibiting the oxidative burst and apoptotic pathways, among others, virotransducer proteins exert their effects [20, 21]. In addition to their intracellular activity, virostealth proteins suppress immunological recognition molecules such as major histocompatibility complex class 1 (MHC 1) and CD4 [24,25,26]. One form of external protein, viromimic proteins, helps monkeypox evade the host's immune response, while two types of intracellular modulatory proteins do the same. Viromimic proteins may be divided into two classes, as shown in Figure 2, and they both play a role in influencing the immune system's reaction. Viroreceptors are glycoproteins that can be found on the cell surface or secreted and bind competitively to host cytokines and chemokines, blocking their effects [27, 28]. Consequently, virokines generate viral mimics of host cytokines, chemokines, and growth factors that are efficient at both counteracting host responses that are deleterious to virus survival and encouraging responses suitable for viral replication and dissemination [29,30]. All of these modulatory proteins collaborate to fool the host immune system and spread virus. The ability of monkeypox and other orthopoxviruses to avoid the immune system is dependent on the presence of certain proteins.



**FIGURE 2:** Intracellular and Extracellular Proteins of Monkeypox

## EPIDEMIOLOGY AND HISTORICAL OUTBREAKS

Specifically, the nations of Cameroon, the Central African Republic, Côte d'Ivoire, the Democratic Republic of the Congo (DRC), Gabon, Liberia, Nigeria, the Republic of the Congo, and Sierra Leone all have monkeypox as an endemic disease in their tropical rainforest regions. The vast majority of cases occur unexpectedly or within the framework of regional epidemics [31,32]. Outbreaks in non-endemic regions are frequently associated with either human travel or the importation of infected animals [33, 34]. Outside of Africa, instances have been documented in the United States, the United Kingdom (UK), Israel, and Singapore by 2022 [35]. The MPXV has two genetic subgroups, or clades: The Central African clade and the West African clade [36]. Historically, the Central African (Congo Basin) clade has been linked to higher transmissibility and case-fatality ratios as high as 10% [37], whereas infection with the West African clade is typically associated with a more self-limited disease with estimated case-fatality ratios of approximately 3-6%. In all of Africa, only in Cameroon have both clades been established [38, 39]. Related to the high number of cases recorded in past and present outbreaks in the DRC, more instances of the Central African clade have been re-reported to date than those due to the West African clade [40]. During the multi-country outbreaks of 2022, the West African clade of MPXV was separated from cases in newly impacted nations. Three points sum up the differences between endemic and nonendemic transmission of monkeypox. Spread from animals to humans takes place via bites and scratches. Spread may also occur during the preparation and handling of affected animal products (bush- meat [41]). There has been no breakthrough in pinpointing the animal species that serves as the definitive reservoir for MPXV. Small mammals and nonhuman primates are only two of the animal taxa from which the virus has been isolated. When MPXV was first isolated from wild animals, it was found that the animals had lesions resembling chicken pox [42–47]. We do not know if MPXV is carried asymptotically in the animal reservoir. Captive animals have been tested for antibodies in endemic areas, while studies of wild mammals have used serology. Several different animal species have been discovered to contain OPXV-specific antibodies in these investigations, despite the lack of viremia as measured by polymerase chain reaction (PCR). This indicates that zoonotic OPXV is present and circulating across many species of wild animals [48]. It is believed that the virus can spread from person to person either by direct skin-to-skin contact with open sores or through indirect contact with contaminated fomites, such as shared linens or clothes [49]. Even in close quarters, the virus can be spread by exchanging respiratory secretions that are still alive and infectious. Over the past half-century, monkeypox has caused the most damage in the Democratic Republic of the Congo, followed by Nigeria and the Republic of the Congo. Since 1970, when the first human case was discovered in a 9-month-old kid in a rural community in the DRC [50], the recorded outbreaks of human monkeypox are summarised in Table 1. The global elimination of smallpox in the 1970s prompted increased surveillance for pox-like infections in tropical rainforest regions, which has helped detect monkeypox outbreaks as they have occurred. Importantly, cross-protection against MPXV infection is provided by smallpox vaccinations, which were formerly offered worldwide until the 1970s. There has been an upsurge in sporadic outbreaks and cases over the world in the last 15 years [51]. This may be due to a combination of causes, including the gradual decline in immunity towards smallpox over time.

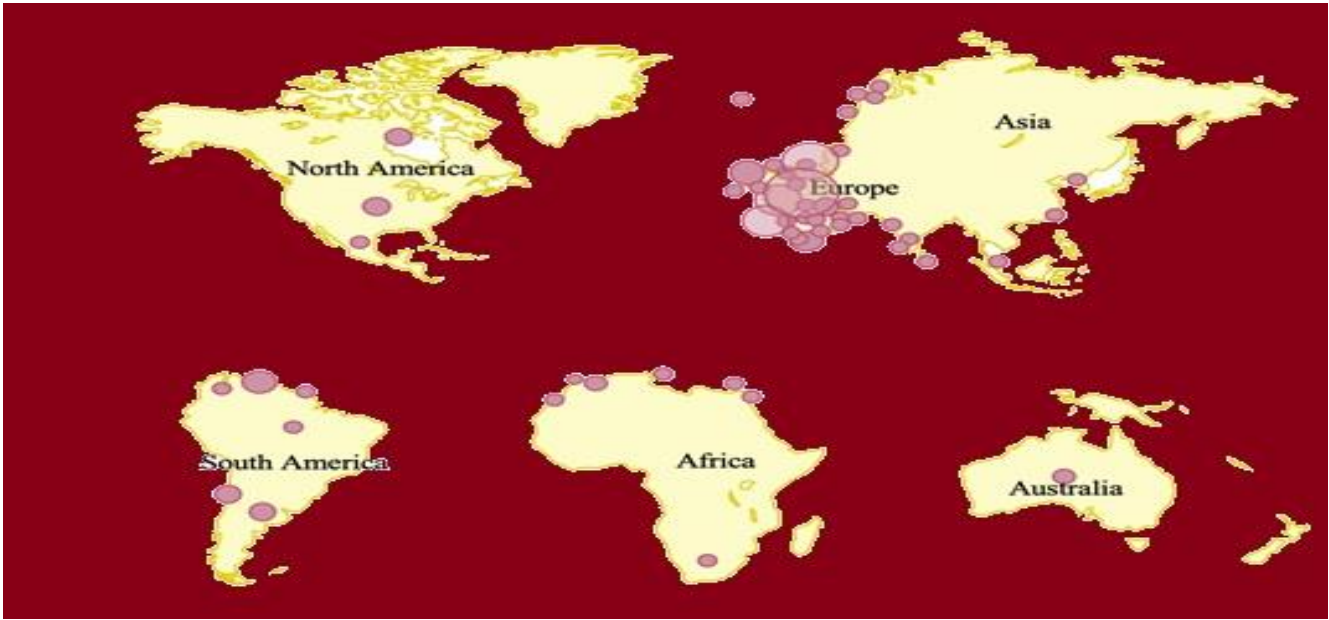


FIGURE 3: Current Regional Distribution of Confirmed Cases of Monkeypox

### PROPOSED PATHOGENESIS OF MONKEYPOX

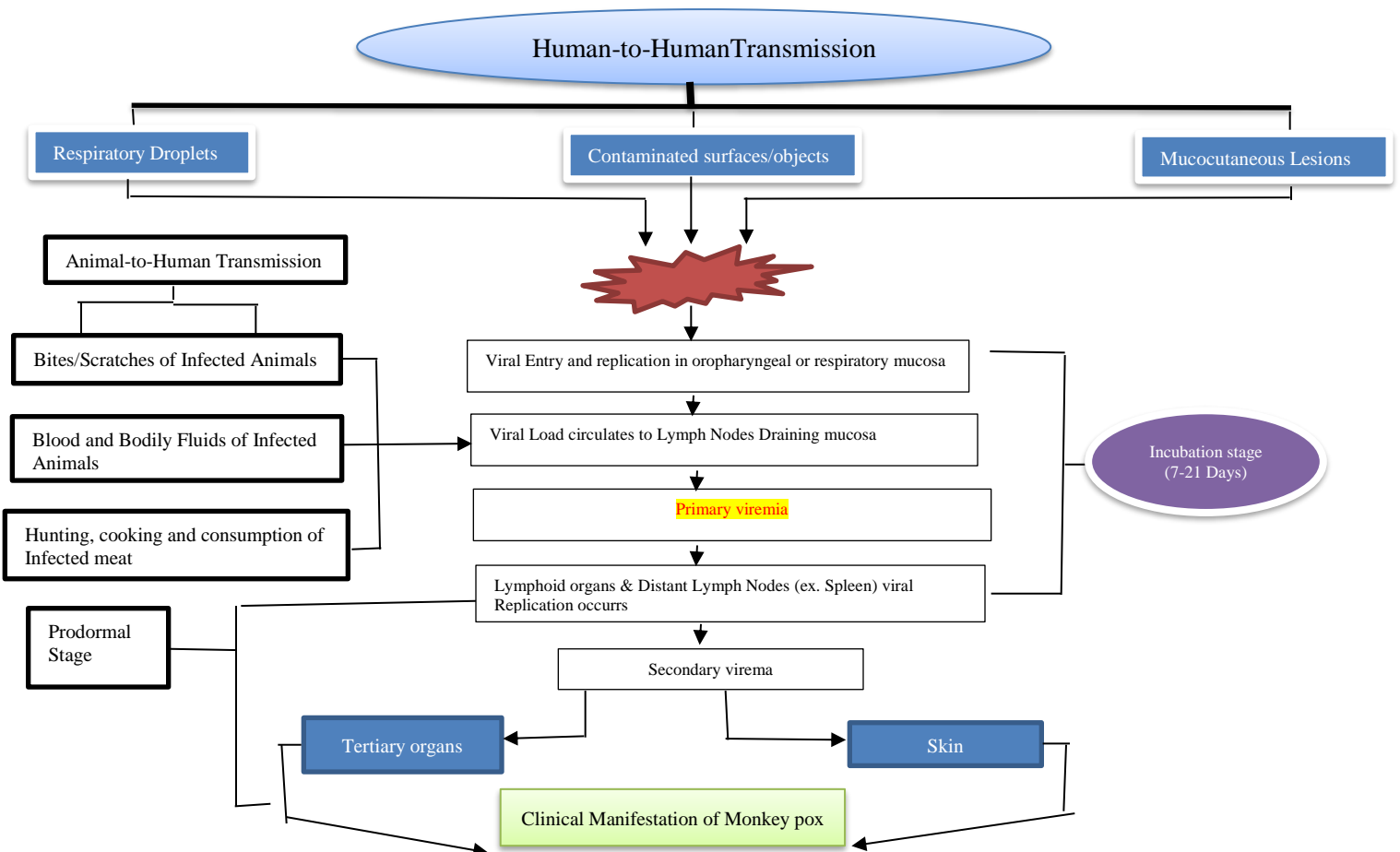
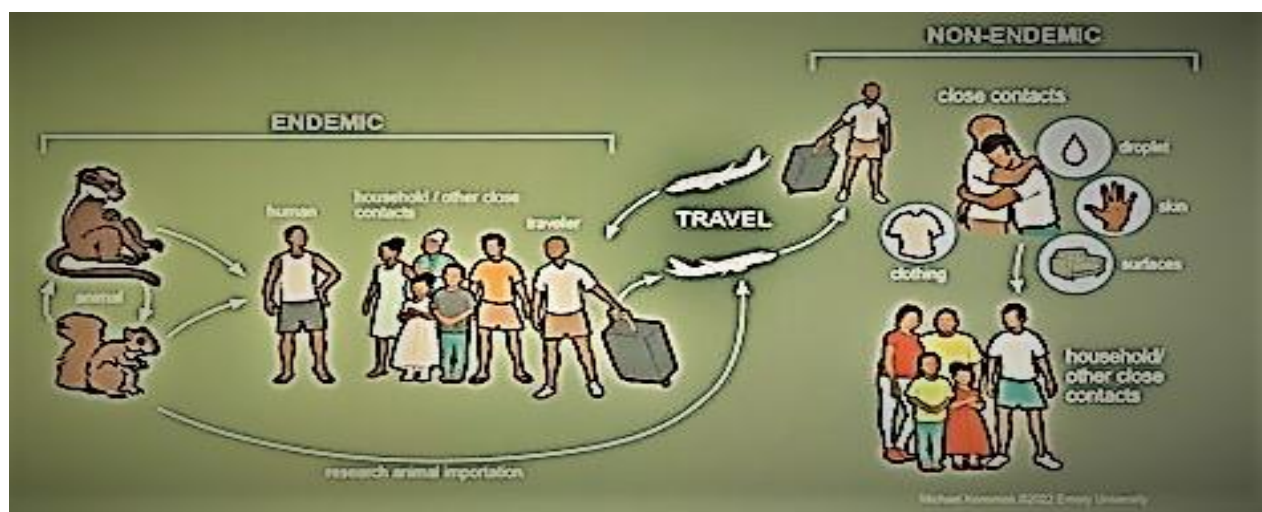


FIGURE 4: Pathogenesis of Monkeypox



**Figure 5.** Monkeypox spread. In endemic nations, zoonotic animal reservoirs can overflow into people, causing epidemics encouraged by close human contact. Human travel or animal imports can cause outbreaks in nonendemic locations. Household and other close connections can then spread the disease.

## CLINICAL PRESENTATION

People who are male, under the age of 15, and lack immunity to smallpox are more likely to contract monkeypox in a sylvatic situation where exposure is likely to occur [52]. Patients have traditionally reported prodromal symptoms such as fever, headache, chills, malaise, and lymphadenopathy prior to the appearance of the classic rash. Rash symptoms typically begin in the mouth, progressing to the face, hands, and feet. Each lesion manifests as a macule before developing into subsequent stages including papules, vesicles, pustules, and scabs. Though severe pain is a common symptom, it is not always present, and pruritus may develop when the lesions are healing. Monkeypox skin lesions are often smaller than those caused by chickenpox, and appear earlier than those caused by that virus. Lesions can range from tens to hundreds, and they can stick around for up to four weeks [53,54]. As soon as symptoms begin (which are assumed to include prodromal symptoms before to the rash's development), the patient is contagious until the lesions scab over and fall off, at which point a new layer of skin forms. A bacterial superinfection, encephalitis, pneumonitis, and conjunctivitis/keratitis are all extremely unusual but possible outcomes of monkeypox [56,57]. We don't have a good idea of how often issues arise or how long it takes for them to appear. While there are many similarities between monkeypox and smallpox, monkeypox often has a milder course and manifests with lymphadenopathy, which was typically absent in smallpox infection. It's also worth noting that the skin symptoms of monkeypox might look like those of other infections including chickenpox, molluscum contagiosum, herpes simplex virus, syphilis, impetigo, early-stage measles, and rickettsial disorders. Many victims of the current 2022 epidemic of monkey pox have presented with non-typical symptoms. Even though the classic rash is always there, it may just affect the vaginal, perigenital, and perianal regions, or it may only appear at a later stage. Additionally, patients may present with nonexistent or moderate prodromal symptoms that develop after the initial manifestation of a localised rash. As doctors strive to make an accurate diagnosis of patients and the globe works to limit the epidemic, it is crucial to take into account a broad range of illness manifestations.

## DIAGNOSIS

A strong index of suspicion for monkeypox infection and knowledge of the unusual monkeypox presentations observed during the current 2022 outbreak are both crucial. Clinicians should inquire about the patient's sexual and travel history, as well as whether or not the patient has had close contact with somebody who has exhibited symptoms comparable to those of monkeypox. Sleeping in the same bed, sharing utensils at mealtimes, using the same dishes at home, etc. are all examples of the kinds of actions that are considered to be very close [59]. In addition, a lack of a travel history or a specific known close contact with a rash or with a suspected or confirmed monkeypox infection does not rule out the probability of this diagnosis. It's also important to check the skin thoroughly.

**Table 1.** Outbreaks of Monkeypox: 1970–2021

Decade	1970–1979	1980–1989	1990–1999	2000–2009	2010–2019	2020–2021			
Endemic Countries	Number of Cases Reported* by Decade						Total Cases	Deaths	References
Cameroon <sup>a</sup>	1	1	— <sup>b</sup>	—	16	—	18	N/A	[28,32]
Central African Republic	—	8	—	—	61	—	69	0	[7, 21, 33–38]
Côte d’Ivoire	1	—	—	—	—	—	2	0	[4, 39]
DRC*	38	343	511	10 027	18 788	7374	37 081	N/A	[4, 18, 22, 39–50]
Gabon	—	4	9	—	—	—	13	N/A	[51–53]
Liberia	4	—	—	—	6	—	10	N/A	[54, 55]
Nigeria	4	—	—	—	228	42	274	N/A	[6, 56, 57]
Republic of the Congo	—	—	—	73	24	—	97	N/A	[58–60]
Sierra Leone	1	—	—	—	2	—	3	0	[61–64]
South Sudan	—	—	—	—	19	—	19	0	[65]
Nonendemic Countries									
Israel	—	—	—	—	1	—	1	0	[66]
Singapore	—	—	—	—	1	—	1	0	[67]
United Kingdom	—	—	—	—	4	—	4	0	[68,69]
United States	—	—	—	47	—	2	49	0	[5,]

A skin lesion specimen sent for molecular testing by PCR is the best course of action for a patient suspected of having an active monkeypox infection. Samples should be collected from at least two un-roofed lesions located on various areas of the body in order to capture representative amounts of virus-containing secretions. While some labs are equipped to provide direct PCR testing for MPXV, others only test for OPXV, which then needs to be confirmed by testing for MPXV at a reference lab. While in the context of the current epidemic, it is reasonable to presume that a positive OPXV test represents a diagnosis of monkeypox infection even before findings from confirmatory tests are available. When possible, public health authorities should be consulted about testing plans before samples are collected. Virus strains for further characterisation can be obtained by cell culture, however this can only be done in approved biosafety level 3 reference laboratories [60]. The use of serological testing has the potential to aid in the study of epidemiology, the diagnosis of prior illnesses, and the identification of late clinical symptoms like encephalitis. Cross-reactivity between MPXV serology and previous smallpox immunisation is possible, but poses little risk to unprotected persons [66,67].

## CLINICAL MANAGEMENT AND TREATMENT

There are no present therapies for monkeypox illness; but, the vaccinia vaccine, cidofovir, tecovirimat, and vaccinia immune globulin (IVG) may be useful in the future based on their success in combating smallpox [61]. According to the World Health Organization, in 2022 the European Medicines Agency (EMA) approved the use of tecovirimat treating monkeypox [69]. Because tecovirimat is not yet widely available, its usage needs to be tracked closely. By blocking viral DNA polymerase, cidofovir has antiviral action against a wide range of viruses [62]. Variola, vaccinia, cowpox, ectromelia, rabbitpox, and monkeypox are only some of the orthopoxviruses that have been shown to be effectively treated with tecovirimat. Monkeypox may be treatable with tecovirimat, an intracellular viral release inhibitor taken orally. A monkeypox virus infection is managed mostly by supportive and symptomatic treatment, despite the various methods proposed for doing so. Options for supportive therapy that may be helpful to those experiencing symptoms are included in Table 2. No specific therapy exists for monkeypox; at most, symptoms can be managed and consequences avoided. Further study is required before any therapy or vaccination can be ordered in light of the 2003 monkeypox epidemic in the United States and the current report of monkeypox patients abroad.

**Table: 2-Clinical Management**

Symptom/Complication	Supportive Treatment
Respiratory distress/Bronchopneumonia	Oral/intravenous antibiotics for prophylaxis, nebulizer treatments, non-invasive ventilation (ex. CPAP)
Sepsis	Oral/intravenous antibiotics, supplemental oxygen, corticosteroids, insulin
Gastrointestinal/mouth and throat ulcers	Oral/intravenous antiemetic and antidiarrheal medications, oral/intravenous rehydration
Fever	Antipyretic medications, external cooling
Superinfection skin	Oral/intravenous antibiotics, incision, and drainage, advanced wound management (ex. negative pressure wound therapy)
Inflammation/Lymphadenopathy	Oral/intravenous anti-inflammatory/analgesic medications
Corneal infection	Ophthalmic antibiotics/antivirals and corticosteroids
Skin scarring/Cellulitis/Skin lesions	Application of moist occlusive dressings to promote re-epithelization Lesions

**Table: 3 -Potential Treatment Options for Monkeypox Infection**

Therapy	Mechanism of Action	Typical Dosing	Formulation	FDA Approval Status	Side Effects and Adverse Events
Cidofovir	Blocks viral DNA synthesis through competitive inhibition of DNA polymerase	5 mg/kg per dose once weekly for $\geq 2$ doses (with concomitant probenecid)	IV; off-label: topical, intravesicular	CMV retinitis in patients with AIDS (1996)	Nephrotoxicity; neutropenia; decreased intraocular pressure, nausea, vomiting
Brincidofovir	Lipid conjugate prodrug of cidofovir	4 mg/kg once weekly for 2 doses (max 200 mg/dose)	Oral	Smallpox (2021)	Abdominal pain, nausea, vomiting, diarrhea, elevated liver transaminases and bilirubin
Tecovirimat	Inhibits activity of the protein VP37, which prevents creation of virions that can be released from an infected host cell, thereby preventing replication and dissemination within the host	IV: 35 to <120 kg: 200 mg q12 hours $\geq 120$ kg: 300 mg q12 hours Oral: 40 to <120 kg: 600 mg q12 hours $\geq 120$ kg: 600 mg q8 hours All regimens for 14 days	IV and oral (off-label topical)	Smallpox (2018)	IV: pain and swelling at infusion site; extravasation at infusion site; headache Oral: headache, abdominal pain, nausea, vomiting
VIGIV	Passive immunity through OPXV-specific antibodies collected from pooled human plasma of persons immunized with smallpox vaccine	6000 units/kg as a single dose (up to 9000 units/kg) Dose can be repeated depending upon symptoms	IV	Complications of vaccinia vaccination (progressive vaccinia, severe generalized vaccinia, etc) (2005)	Infusion reaction; local injection-site reaction (contraindicated in persons with IgA deficiency and possible IgA hypersensitivity)

**Table 4.** Clinical Use of Antiviral Agents and Vaccinia Immunoglobulin for Treatment of Orthopoxvirus Infections

Type of OPXV	Year	Clinical Scenario	Cidofovir	Brincidofovir	Tecovirimat	VIGIV
Vaccinia	1987	Progressive vaccinia in a patient with undiagnosed HIV/AIDS	(-)	(-)	(-)	(+) (given IM)
Vaccinia	2008	28-month-old with severe eczema vaccinatum after contact with family member who received smallpox vaccination	(+)	(-)	(+)	(+)
Vaccinia	2012	Progressive vaccinia in a patient with undiagnosed AML	(-)	(+)	(+) (also administered topically)	(+)
Vaccinia virus	2013	Cluster of cases with secondary and tertiary transmission after sexual contact with a recipient of smallpox vaccination (2 total cases)	(-)	(-)	(-)	(+)
Cowpox	2015	Severe ocular infection in a patient with underlying atopic dermatitis	(-)	(-)	(+)	(-)
Cowpox	2016	17-year-old with a kidney transplant with fatal disseminated infection	(+)	(+)	(-)	(+)
Vaccinia	2019	Prophylactic treatment of potential severe vaccinia infection in a patient with undiagnosed AML	(-)	(-)	(+)	(+)
Vaccinia	2019	Patient with Crohn's disease with secondary vaccinia lesions	(-)	(-)	(+)	(+)
Vaccinia	2019	Patient with acne and secondary vaccinia lesions	(-)	(-)	(+)	(+)
Cowpox	2019	Severe keratoconjunctivitis due to cowpox	(-)	(-)	(+)	(-)
Vaccinia	2019	Laboratory worker who had a needlestick exposure	(-)	(-)	(+)	(+)
Cowpox	2021	Severe orbital infection due to contact with an infected cat	(-)	(-)	(+)	(-)
MPXV	2022	Travel-associated case of MPXV infection in the United States	(-)	(-)	(+)	(-)
MPXV	2022	MPXV infection in travelers returning to the United Kingdom (7 total patients)	(-)	(+) (3 of 7 patients)	(+) (1/7 patients)	(-)
MPXV	2022	Initial report on cases related to 2022 outbreak of MPXV infections in the United States (17 total patients)	(-)	(-)	(+) (1/17 patients)	(-)

## CURRENT TRENDS AND FUTURE DIRECTIONS

Two cases of monkeypox in the same family were recorded in the United Kingdom on May 14, 2022; neither person had been to an epidemic zone. There have been thousands of instances documented since then throughout several nations in Europe, South America, the Middle East, Canada, and the United States. The vast majority of reported instances have involved males between the ages of 25 and 35, with many of those individuals identifying as homosexual, bisexual, or other MSM. Atypical presentations in the clinic have included vaginal, perigenital, and perianal lesions, which point to the potential importance of close personal encounters during sex in the spread of the disease. Extensive research is being conducted to see if there is any evidence that monkeypox may be spread sexually. Case in point: in Italy and Germany, tiny quantities of virus have been extracted from patient sperm. Public health officials in the UK advise abstinence during active infection and for up to 8 weeks following recovery [63] until more is known about the role of sexual transmission. Some nations are presently attempting to limit the epidemic by implementing techniques such as pre-exposure vaccination of gay/bisexual and other MSM and prioritising vaccination of close contacts of case-patients (known as ring-vaccination) as PEP. Transmission networks have emerged in numerous nations outside of regions where monkeypox is prevalent, making the current worldwide outbreak one of the largest in history. The unusually lengthy incubation period of MPXV, along with an initially low index of suspicion among doctors unfamiliar with the illness, implies that local transmission leading to big clusters may have gone undetected for some time. Comparisons have been made between the early stages of the coronavirus disease 2019 (COVID-19) pandemic and the multicountry outbreaks of monkeypox, despite the fact that the world is still in the midst of a global pandemic caused by

another emerging zoonotic virus, severe acute respiratory syndrome coronavirus 2 (SARS-CoV-2). While terrible, the present monkeypox scenario is unique. Current monkeypox epidemics are not expected to cause a worldwide pandemic on the size of COVID-19. Since MPXV has been around before, we know what to do to stop it from spreading. In addition, monkeypox is spread in a very different way than SARS-CoV-2. Unfortunately, many medical professionals have not had much experience with monkeypox and hence are not very good at either diagnosing or treating it.[64]

To effectively contain the present outbreak, it will be necessary to define its features. To better detect cases and define the breadth of the epidemic, healthcare facilities should use screening technologies and maintain a high degree of suspicion using developing clinical case definitions. Limiting new infections and breaking transmission chains will require early isolation of suspected and confirmed cases, as well as rigorous monitoring of close contacts and vaccination of healthcare personnel with high-risk exposures. Given the diversity of its hosts, monkeypox's current epidemic has prompted legitimate fears that the disease would spread outside Africa and into new enzootic and endemic areas. Clustering of cases in gay/bisexual and other MSM has unfortunately led to unacceptable stigma aimed towards this group of people, reminiscent of the early days of the human immunodeficiency virus (HIV)/acquired immune deficiency syndrome pandemic. When it comes to combating prejudice and discrimination caused by HIV and other infectious illnesses, the infectious disease community has been, and remains, at the forefront of the effort. With this new epidemic, we must respond in the same way. The foundation of our public health messaging should be encouraging and non-judgmental, but efforts should be focused on identifying instances in social networks that are emerging as having a greater risk for exposure. It is important to constantly educate our peers and the general public that contagious viruses do not discriminate on the basis of race, gender, or sexual orientation.[65]

## CONCLUSIONS

As we continue to look for new cases, we will have a better idea of the scope of the current epidemic over the course of the next several months. It will be extremely important to respond promptly and aggressively in order to contain it. The most important factor in determining our level of success will be how well we are able to use the lessons we have gained from prior epidemics and how well we communicate our available resources. Since the beginning, there have been signs that monkeypox might one day become a major problem for the health of people all around the world. Now is the time to adopt a truly global approach that addresses this problem in a definitive manner not only in wealthy countries but also, critically, in endemic countries that have been responding to monkeypox for decades. This approach should address the issue not only in wealthy countries but also in countries where monkeypox is naturally occurring.

## ACKNOWLEDGEMENTS

We are thankful to Prof (Dr.) Ranjit Singh Vice-Chancellor Shobhit University, Gangoh, Saharanpur Uttar Pradesh, for their kindly support for my work. We are grateful to the technical staff members of the Department of Pharmaceutical Sciences. We also thank the following persons: Dr. Niladry Sekhar Ghosh, and Dr.M.K Gupta, Mr. Debashis Purohit.

## DECLARATIONS

Conflict of Interest -The authors declare no potential conflicts of interest.

Ethical Approval -This Article does not contain any studies with human participants or animals performed by the author.

## REFERENCES

1. European Center for Disease Control. Epidemiological update: monkeypox outbreak. Available at: <https://www.ecdc.europa.eu/en/news-events/epidemiological-update-monkeypox-outbreak>. Accessed 31 May 2022.
2. World Health Organization. Multi-country monkeypox outbreak: situation update. Available at: <https://www.who.int/emergencies/disease-outbreak-news/item/2022-DON392>. Accessed 15 June 2022.
3. Magnus PV, Andersen EK, Petersen KB, et al. A pox-like disease in cynomolgus monkeys. *Acta Pathol Microbiol Scand* 1959; 46:156–76. doi:10.1111/j.1699-0463.1959.tb00328.x
4. Breman JG, Kalisa R, Steniowski MV, Zannoto E, Gromyko AI, Arita I. Human monkeypox, 1970–79. *Bull World Health Organ* 1980; 58:165–82.
5. Reed KD, Melski JW, Graham MB, et al. The detection of monkeypox in humans in the western hemisphere. *N Engl J Med* 2004; 350:342–50. doi:10.1056/NEJMoa032299
6. Alakunle E, Moens U, Nchinda G, et al. Monkeypox virus in Nigeria: infection biology, epidemiology, and evolution. *Viruses* 2020; 12:1257. doi:10.3390/v12111257
7. Bunge EM, Hoet B, Chen L, et al. The changing epidemiology of human monkeypox-a potential threat? A systematic review. *PLoS Negl Trop Dis* 2022; 16:e0010141. doi:10.1371/journal.pntd.0010141
8. Di Giulio DB, Eckburg PB. Human monkeypox: an emerging zoonosis. *Lancet Infect Dis* 2004; 4:15–25. doi:10.1016/S1473-3099(03)00856-9
9. Knipe DM, Howley PM. *Fields Virology*, 6th Edition: Lippincott Williams & Wilkins, Philadelphia, PA; 2013.
10. McFadden G. Poxvirus tropism. *Nat Rev Microbiol* 2005; 3:201–13. doi:10.1038/nrmicro1099
11. Oliveira GP, Rodrigues RAL, Lima MT, et al. Poxvirus host range genes and virus-host spectrum: a critical review. *Viruses* 2017; 9:331. doi:10.3390/v9110331
12. Shchelkunov SN, Marennikova SS, Moyer RW. *Orthopoxviruses Pathogenic to Humans*. New York, NY: Springer, 2005.
13. Fenner F, Henderson DA, Arita I, Jezek Z, Ladnyi ID. *Smallpox and its eradication*. Geneva: World Health Organization, 1988.

14. Haller SL, Peng C, McFadden G, et al. Poxviruses and the evolution of host range and virulence. *Infect Genet Evol* 2014; 21:15–40. doi:10.1016/j.meegid.2013.10.014
15. Fine PE, Jezek Z, Grab B, et al. The transmission potential of monkeypox virus in human populations. *Int J Epidemiol* 1988; 17:643–50. doi:10.1093/ije/17.3.643
16. Esposito JJ, Sammons SA, Frace AM, et al. Genome sequence diversity and clues to the evolution of variola (smallpox) virus. *Science* 2006; 313:807–12. doi: 10.1126/science.1125134
17. Shchelkunov SN. An increasing danger of zoonotic orthopoxvirus infections. *PLoS Pathog* 2013; 9:e1003756. doi:10.1371/journal.ppat.1003756
18. Rimoin AW, Mulembakani PM, Johnston SC, et al. Major increase in human monkeypox incidence 30 years after smallpox vaccination campaigns cease in the Democratic Republic of Congo. *Proc Natl Acad Sci U S A* 2010; 107: 16262–7. doi:10.1073/pnas.1005769107
19. Rao AK, Schulte J, Chen TH, et al. Monkeypox in a traveler returning from Nigeria–Dallas, Texas, July 2021. *MMWR Morb Mortal Wkly Rep* 2022; 71: 509–16. doi:10.15585/mmwr.mm7114a1
20. Nakazawa Y, Mauldin MR, Emerson GL, et al. A phylogeographic investigation of African monkeypox. *Viruses* 2015; 7:2168–84. doi:10.3390/v7042168
21. Berthet N, Descorps-Declère S, Besombes C, et al. Genomic history of human monkey pox infections in the Central African Republic between 2001 and 2018. *Sci Rep* 2021; 11:13085. doi:10.1038/s41598-021-92315-8
22. Meyer H, Perrichot M, Stemmler M, et al. Outbreaks of disease suspected of being due to human monkeypox virus infection in the Democratic Republic of Congo in 2001. *J Clin Microbiol* 2002; 40:2919–21. doi:10.1128/JCM.40.8.2919-2921.2002
23. Khodakevich L, Jezek Z, Kinzanzka K. Isolation of monkeypox virus from wild squirrel infected in nature. *Lancet* 1986; 1:98–9. doi:10.1016/S0140-6736(86)90748-8
24. Radonić A, Metzger S, Dabrowski PW, et al. Fatal monkeypox in wild-living sooty mangabey, Côte d’Ivoire, 2012. *Emerg Infect Dis* 2014; 20:1009–11. doi: 10.3201/eid2006.131329
25. Patrono LV, Pléh K, Samuni L, et al. Monkeypox virus emergence in wild chimpanzees reveals distinct clinical outcomes and viral diversity. *Nat Microbiol* 2020; 5:955–65. doi:10.1038/s41564-020-0706-0
26. Falendysz EA, Lopera JG, Doty JB, et al. Characterization of monkeypox virus infection in African rope squirrels (*funisciurus* sp.). *PLoS Negl Trop Dis* 2017; 11:e0005809. doi:10.1371/journal.pntd.0005809
27. Doty JB, Malekani JM, Kalemba LN, et al. Assessing monkeypox virus prevalence in small mammals at the human-animal interface in the Democratic Republic of the Congo. *Viruses* 2017; 9:283. doi:10.3390/v9100283
28. Guagliardo SAI, Monroe B, Moundjoa C, et al. Asymptomatic orthopoxvirus circulation in humans in the wake of a monkeypox outbreak among chimpanzees in Cameroon. *Am J Trop Med Hyg* 2020; 102:206–12. doi:10.4269/ajtmh.19-0467
29. Tchokoteu PF, Kago I, Tetanye E, Ndoumbe P, Pignon D, Mbede J. [Variola or a severe case of varicella? A case of human variola due to monkeypox virus in a child from the Cameroon]. *Ann Soc Belg Med Trop* 1991; 71:123–8.
30. World Health Organization. Regional office for A. Weekly bulletin on outbreak and other emergencies: week 31: 28 July - 3 August 2018. *Week Bulletin Outbreak Emergen* 2018:1–24.
31. World Health Organization. Regional Office for A. Weekly bulletin on outbreak and other emergencies: week 41: 05-11 October 2020. *Week Bulletin Outbreak Emergen* 1-18
32. World Health Organization. Regional office for A. Weekly bulletin on outbreak and other emergencies: week 01: 30 December 2019–05 January 2020. *Week Bulletin Outbreak Emergen* 2020: 1-14.
33. Berthet N, Nakouné E, Whist E, et al. Maculopapular lesions in the Central African Republic. *Lancet* 2011; 378:1354. doi:10.1016/S0140-6736(11)61142-2
34. Nakoune E, Lampaert E, Ndjapou SG, et al. A nosocomial outbreak of human monkeypox in the Central African Republic. *Open Forum Infect Dis* 2017; 4: ofx168. doi:10.1093/ofid/ofx168
35. Kalthan E, Tenguere J, Ndjapou SG, et al. Investigation of an outbreak of monkeypox in an area occupied by armed groups, Central African Republic. *Med Mal Infect* 2018; 48:263–8. doi:10.1016/j.medmal.2018.02.010
36. World Health Organization. Weekly bulletin on outbreak and other emergencies: week 31: 29 July-04 August 2019. Available at: <https://apps.who.int/iris/handle/10665/326159>. Accessed May 30, 2022 .
37. reliefweb. Monkeypox in Central African Republic. Available at: <https://reliefweb.int/report/central-african-republic/monkeypox-central-african-republic>. Accessed 31 May 2022.
38. reliefweb. Central African Republic: Monkey Pox Outbreak–December 2015. Available at: <https://reliefweb.int/disaster/ep-2015-000178-caf>. Accessed 31 May 2022.
39. Mwanbal PT, Tshioko KF, Moudi A, et al. Human monkeypox in Kasai Oriental, Zaire (1996–1997). *Euro Surveill* 1997; 2:33–5. doi:10.2807/esm.02.05.00161-en
40. Rimoin AW, Kisalu N, Kebela-Ilunga B, et al. Endemic human monkeypox, Democratic Republic of Congo, 2001–2004. *Emerg Infect Dis* 2007; 13:934–7. doi:10.3201/eid1306.061540
41. Jezek Z, Arita I, Mutombo M, Dunn C, Nakano JH, Szczeniowski M. Four generations of probable person-to-person transmission of human monkeypox. *Am J Epidemiol* 1986; 123:1004–12. doi:10.1093/oxfordjournals.aje.a114328
42. Jezek Z, Grab B, Szczeniowski M, Paluku KM, Mutombo M. Clinico-epidemiological features of monkeypox patients with an animal or human source of infection. *Bull World Health Organ* 1988; 66:459–64.
43. McCollum AM, Nakazawa Y, Ndongala GM, et al. Human monkeypox in the Kivus, a conflict region of the Democratic Republic of the Congo. *Am J Trop Med Hyg* 2015; 93:718–21. doi:10.4269/ajtmh.15-0095
44. Whitehouse ER, Bonwitt J, Hughes CM, et al. Clinical and epidemiological findings from enhanced monkeypox surveillance in Tshuapa province, Democratic Republic of the Congo during 2011–2015. *J Infect Dis* 2021; 223:1870–8. doi:10.1093/infdis/jiab133
45. Nolen LD, Osadebe L, Katomba J, et al. Extended human-to-human transmission during a monkeypox outbreak in the Democratic Republic of the Congo. *Emerg Infect Dis* 2016; 22:1014–21. doi:10.3201/eid2206.150579
46. Eltvéd AK, Christiansen M, Poulsen A. A case report of monkeypox in a 4-year-old boy from the DR Congo: challenges of diagnosis and management. *Case Rep in Pediatr* 2020; 2020:8572596. doi:10.1155/2020/8572596
47. Fuller T, Thomassen HA, Mulembakani PM, et al. Using remote sensing to map the risk of human monkeypox virus in the Congo basin. *Ecohealth* 2011; 8: 14–25. doi:10.1007/s10393-010-0355-5
48. Hoff NA, Doshi RH, Colwell B, et al. Evolution of a disease surveillance system: an increase in reporting of human monkeypox disease in the Democratic Republic of the Congo, 2001–2013. *Int J Trop Dis Health* 2017; 25: IJTDH.35885 doi:10.9734/IJTDH/2017/35885.
49. Centers for Disease Control and Prevention. Human Monkeypox – Kasai Oriental, Democratic Republic of Congo, February 1996–October 1997.

Available at: <https://www.cdc.gov/mmwr/preview/mmwrhtml/00050245.htm>. Accessed 31 May 2022.

50. World Health Organization. 1997-Monkeypox in the Democratic Republic of Congo (former Zaire). Available at: [https://www.who.int/emergencies/disease-outbreak-news/item/1997\\_07\\_31b-en](https://www.who.int/emergencies/disease-outbreak-news/item/1997_07_31b-en). Accessed 31 May 2022.
51. Meyer A, Esposito JJ, Gras F, Kolakowski T, Fatras M, Muller G. [First appearance of monkey pox in human beings in Gabon]. *Med Trop (Mars)* 1991; 51: 53–7.
52. Müller G, Meyer A, Gras F, Emmerich P, Kolakowski T, Esposito JJ. Monkeypox virus in liver and spleen of child in Gabon. *Lancet* 1988; 1:769–70. doi:10.1016/S0140-6736(88)91580-2.
53. World Health Organization. Regional office for Africa HEP. Weekly bulletin on outbreaks and other emergencies: week 1: 30 December 2017-5 January 2018. Brazzaville: World Health Organization. 2018.
54. Eteng WE, Mandra A, Doty J, et al. Notes from the field: responding to an outbreak of monkeypox using the one health approach-Nigeria, 2017–2018. *MMWR Morb Mortal Wkly Rep* 2018; 67:1040–1. doi:10.15585/mmwr.mm6737a5
55. reliefweb. Monkeypox Outbreak in Nigeria: Situation Report #12 (December 2019). Available at: <https://reliefweb.int/report/nigeria/monkeypox-outbreak-nigeria-situation-report-12-december-2019>. Accessed 31 May 2022.
56. Foster SO, Brink EW, Hutchins DL, et al. Human monkeypox. *Bull World Health Organ* 1972; 46:569–76.
57. reliefweb. WHO AFRO Outbreaks and Other Emergencies, Week 16: 15–21 April 2017 (Data as reported by 17:00, 21 April 2017). Available at: <https://reliefweb.int/report/sierra-leone/who-afro-outbreaks-and-other-emergencies-week-16-15-21-april-2017-data-reported>. Accessed 31 May 2022.
58. Dubey, A., Ghosh, N. S., Rathor, V. P. S., Patel, S., Patel, B., & Purohit, D. (2022). Sars- COV-2 infection leads to neurodegenerative or neuropsychiatric diseases. *International Journal of Health Sciences*, 6(S3), 2184–2197. <https://doi.org/10.53730/ijhs.v6nS3.5980>
59. Dubey, Anubhav, Niladry Sekhar Ghosh, Nidhee Agnihotri and Amit Kumar et al. “Herbs Derived Bioactive Compounds and their Potential for the Treatment of Neurological Disorders.” *Clin Schizophr Relat Psychoses* 16 (2022). Doi: 10.3371/CSRP.DANG.081922
60. . Kumar, A. ., Dubey, A. ., & Singh, R. . (2022). Investigation on Anti-Ulcer Activity of Momordica dioica Fruits in Wistar Rat. *International Journal for Research in Applied Sciences and Biotechnology*, 9(1), 105–111. <https://doi.org/10.31033/ijrasb.9.1.12>
61. Dubey Anubhav, Tiwari Mamta, Kumar Vikas, Srivastava, Kshama, Singh, Akanksha. Investigation of Anti-Hyperlipidemic Activity of Vinpocetine in Wistar Rat. *International Journal of Pharmaceutical Research* 2020; 12(02):1879-1882. DOI:<https://doi.org/10.31838/ijpr/2020.12.02.250>
62. Formenty P, Muntasir MO, Damon I, et al. Human monkeypox outbreak caused by novel virus belonging to Congo Basin clade, Sudan, 2005. *Emerg Infect Dis* 2010; 16:1539–45. doi:10.3201/eid1610.100713
63. Erez N, Achdout H, Milrot E, et al. Diagnosis of imported monkeypox, Israel, 2018. *Emerg Infect Dis* 2019; 25:980–3. doi:10.3201/eid2505.190076
64. Yong SEF, Ng OT, Ho ZJM, et al. Imported monkeypox, Singapore. *Emerg Infect Dis* 2020; 26:1826–30. doi:10.3201/eid2608.191387
65. Vaughan A, Aarons E, Astbury J, et al. Two cases of monkeypox imported to the United Kingdom, September 2018. *Euro Surveill* 2018; 23:1800509 doi: 10.2807/1560-7917.ES.2018.23.38.1800509.