

Sub-Acute Toxicological Assessment Of Ethanolic Extract Of *Achyranthes Aspera* L., In Wistar Rats

K. MADHANA GOPAL¹ ; DEEPA KAMESWARI. P¹ , M. MEGANATHAN¹; and K. BALAMURUGAN^{2*}

¹ Department of Pharmacology, Aarupadai Veedu Medical College and Hospital, Puducherry, India.

^{2*} Associate Professor, Department of Pharmacy, FEAT, Annamalai University, Annamalai Nagar, Chidambaram - 608002, Tamil Nadu, India

*Corresponding author:

Dr.K. BALAMURUGAN

Associate Professor, Department of Pharmacy, FEAT, Annamalai University, Annamalai Nagar, Chidambaram - 608002, Tamil Nadu, India. E-mail: placementbala@yahoo.co.in

DOI: 10.47750/pnr.2022.13.S02.79

Abstract

The plant *Achyranthes aspera* L (Amaranthaceae) has diverse ethno medicinal uses, including the analgesic, antipyretic, anti-inflammatory, antiallergic, antiarthritic, antidepressant, antimicrobial, antioxidant, antiparasitic, bronchoprotective, cancer chemo preventive, cardiovascular disorders, diuretic, hepato protective, hypoglycaemic, hypolipidemic activity, immunomodulatory, nephroprotective, spermicidal and wound healing activities. Despite its potential therapeutic uses, the toxicity profile of *Achyranthes aspera* L has not been evaluated. This study assessed the sub-acute toxicity effects of whole plants of *Achyranthes aspera* L ethanolic extract (AAE). The sub-acute toxic effects of the AAE (1000 mg/kg) was investigated following administration of the AAE daily for 28 consecutive days as per the OECD 407 guideline. The weekly body weights were recorded. The animals were euthanized on the 29th day, and blood samples were obtained for hematological and biochemical investigations. The heart, kidney, liver, and lungs were collected for histological examinations. Besides, the relative organ weights were determined.

INTRODUCTION

Achyranthes aspera L., belongs to family Amaranthaceae the common name, prickly chaff flower the vernacular names in Sanskrit - Aghata; Hindi - Chirchira; Malayalam - Kadaladi and in Tamil - Nayuruvi. *Achyranthes aspera* is an erect, annual or perennial herb about 1m to 2m high. The stems are succulent at first, ribbed, form basally woody with age and densely covered with hairs. (1) The leaves of *A. aspera* is opposite, densely clustered towards branch tips, spreading to decurved, mostly broadly ovate or elliptic; apex blunt to abruptly sub- acute; base attenuate; lamina somewhat fleshy, purple-grey, veins often purple, abaxial and adaxial surfaces silky canescent, margins crenulate to create. The flowers are greenish white, numerous in axillary or terminal spikes up to 75 cm long, seeds subcylindrical, truncate at the apex, rounded at the base, reddish brown.(2)

The seeds of *A. aspera* contains α -L-rhamnopyranosyl- (1 - 4) - (β - D-glucopyrano syluronic acid) - (1-3) - oleanolic acid, α -L rhamnopyranosyl - (1 - 4) - (β - D-glucopyranosyl uronic acid) - (1-3)-oleanolic acid-28-O- β -D- glucopyranoside and α - L rhamnopyranosyl-(1 - 4) - (β -Dglucopyranosyl uronic acid)-(1-3)-oleanolic acid-28-O- β -Dglucopyranosyl-(1 - 4)- β -Dglucopyranoside. The ethanolic extracts of the roots of *A. aspera* contains n - hexacos- 14-enoic acid and certain other compounds like strigmasta-5, 22-dien-3- β -ol, trans-13- docasenoic acid, n-hexacosanyl n-decanate, n-hexacos-17-enoic acid, n-hexacos-11- enoic acid and volatile oils. (3,4)

The various parts of plant extracts has the following activities viz. analgesic, antipyretic, anti-inflammatory, antiallergic, antiarthritic, antidepressant, antimicrobial, antioxidant, antiparasitic, bronchoprotective, cancer chemo preventive, cardiovascular disorders, diuretic, hepato protective, hypoglycaemic, hypolipidemic activity,

immunomodulatory, nephroprotective, spermicidal and wound healing activities. (5) A thoughtful attempt has been made here to explore herbal medicines that have a strong traditional or conceptual base and the potential to be useful as antifertility effects in terms of safety and effectiveness. The present study was an attempt to investigate the effects of the whole plants of *Achyranthes aspera* L ethanolic extracts (AAE) for the preliminary test in repeated dose oral toxicity study in rats using OECD 407 guidelines before the antifertility actions in female rats.

MATERIALS AND METHODS

The whole plants of *Achyranthes aspera* L was collected from Kothagiri, Nilgiris district, Tamilnadu and was authenticated by Scientist of Botanical Survey of India, Agricultural University, Coimbatore - 641 003. The plants collected were washed in running water, dried under shade, segregated and pulverized by mechanical grinder and the powder was passed through No 20 sieve. The powdered material was successfully extracted with ethanol by hot continuous percolation method in Soxhlet apparatus for 10 hrs. The residue obtained was then utilized for evaluating sub-acute toxicological assessment by suspending in distilled water in Tween 80 (2%) as suspending agent was given at doses of 200 mg and 400 mg/ kg.

Wistar rats having weight of 180 - 220 gm were kept in quarantine for 10 days under standard husbandry conditions (27 °C, RH 65 ±2 %) for 12 h in dark and light cycle respectively and were given standard food and water ad libitum. All the experiments were performed as per the CPCSEA norms after obtained the approval of the IAEC, C.L.Baid Metha College of Pharmacy, Chennai - 97, Tamil Nadu, (IAEC / II / 02 / CLBMCP / 2013 dated 21.01.2013).

REPEATED DOSE 28-DAYS ORAL TOXICITY STUDY:

28-days oral toxicity study was carried out on adult female young virgin Wistar rats of 180-220 g. body weight, each group containing 6 animals were housed individually in labeled polypropylene cages. Rats were allowed free access to standard pellet diet and tap water ad libitum. Animals were maintained in controlled laboratory conditions of 12 hrs dark/light cycle, 22±2°C temperatures and 45-60% humidity and after 2 weeks of acclimatization, the rats were divided into four groups of 6 each. Group –I, (control group) rats received tween 80 (2%) 1 ml/ kg/p.o suspension; Group –II, AAE treated rats. (6)

Table- 1: Grouping of rats in repeated dose 28-days oral toxicity study

Sl.No	Groups	Treatment
1.	Group-I (Control)	Rats treated with tween 80 (2%) 1 ml/ kg/p.o suspension for 28 days.
2.	Group-IV (AAE treated)	Rats treated with AAE (1000mg / kg/ p.o.) for 1- 28 days.

The extract was administered at a fixed time daily for 28 days and observed twice daily for morbidity/mortality and gross behaviour activity. (7) Body weights of the animals were measured weekly. On the 29th day, after an overnight fast, the rats were anaesthetized with ether and blood samples were collected. The hematological, (8) biochemical analysis (9) and hormonal assays were performed. The organ weights (brain, heart, kidney, liver and uterus) were recorded and necroscopy and histopathological studies were also carried out.

RESULTS:

Table-2 Results of gross behavior studies of AAE at a dose of 1000mg/kg . p.o. in rats.

Sl.no	Time (hrs)
-------	------------

Effect on CNS:		$\frac{1}{2}$	1	$1\frac{1}{2}$	2	$2\frac{1}{2}$	3	$3\frac{1}{2}$	4	5	6	12	24
<u>Spontaneous motor activity:</u>													
1.	Ataxic gait.	-	-	-	-	-	-	-	-	-	-	-	-
2.	Bizarre behaviour	-	-	-	-	-	-	-	-	-	-	-	-
3.	Chronic convulsions	-	-	-	-	-	-	-	-	-	-	-	-
4.	Convulsions	-	-	-	-	-	-	-	-	-	-	-	-
5.	Grooming behaviour	-	-	-	-	-	-	-	-	-	-	-	-
6.	Lying flat on the back	-	-	-	-	-	-	-	-	-	-	-	-
7.	Lying flat on the belly	-	-	-	-	-	-	-	-	-	-	-	-
8.	Lying flat on the side	-	-	-	-	-	-	-	-	-	-	-	-
9.	Narcosis	-	-	-	-	-	-	-	-	-	-	-	-
10.	Opisthotonus	-	-	-	-	-	-	-	-	-	-	-	-
11.	Restlessness	-	-	-	-	-	-	-	-	-	-	-	-
12.	Rolling and jumping	-	-	-	-	-	-	-	-	-	-	-	-
13.	Sleeping	-	-	-	-	-	-	-	-	-	-	-	-
14.	Straub's phenomenon	-	-	-	-	-	-	-	-	-	-	-	-
15.	Timidity	+	+	+	+	+	+	+	+	+	+	+	+
16.	Tonic convulsions	-	-	-	-	-	-	-	-	-	-	-	-
17.	Tremors	-	-	-	-	-	-	-	-	-	-	-	-
18.	Twitches	-	-	-	-	-	-	-	-	-	-	-	-
19.	Writhing	-	-	-	-	-	-	-	-	-	-	-	-
<u>Effect on reflexes:</u>													
20.	Corneal reflexes	-	-	-	-	-	-	-	-	-	-	-	-
21.	Pain following stimulation	-	-	-	-	-	-	-	-	-	-	-	-
22.	Pinna reflex	+	+	+	+	+	+	+	+	+	+	+	+
<u>Effect on autonomic nervous system:</u>													
23.	Cyanosis	-	-	-	-	-	-	-	-	-	-	-	-
24.	Defecation	-	-	-	-	-	-	-	-	-	-	-	-
25.	Eyelids(closure/exophthalmus)	-	-	-	-	-	-	-	-	-	-	-	-
26.	Lacrimation	-	-	-	-	-	-	-	-	-	-	-	-
27.	Piloerection	-	-	-	-	-	-	-	-	-	-	-	-
28.	Pupil diameter (constriction/dilatation)	-	-	-	-	-	-	-	-	-	-	-	-
29.	Salivation	-	-	-	-	-	-	-	-	-	-	-	-
30.	Secretion of sweat	-	-	-	-	-	-	-	-	-	-	-	-
31.	Urination	-	-	-	-	-	-	-	-	-	-	-	-
<u>Effect after manipulations:</u>													
32.	Auditory stimulus response	+	+	+	+	+	+	+	+	+	+	+	+
33.	Catalepsy in induced position	-	-	-	-	-	-	-	-	-	-	-	-
34.	Escape after touch	+	+	+	+	+	+	+	+	+	+	+	+
35.	Paralysis of fore paws	-	-	-	-	-	-	-	-	-	-	-	-
36.	Paralysis of hind limbs	-	-	-	-	-	-	-	-	-	-	-	-
37.	Writhing reflex	-	-	-	-	-	-	-	-	-	-	-	-

(-): Normal or non response, (+): positive response

Table-3 Results of the hematological parameters of AAE(1000 mg/kg/oral) in rats

Test	Control	AAE (1000 mg/kg/oral)
WBC (thous/mcl)	8.46±1.87	9.98±1.47
RBC (mill/mcl)	8.64±2.58	8.69±1.89
Hb (g/dl)	15.94±3.46	15.88±2.98
MCV (fl)	58.64± 3.24	56.14±2.38
MCH (pg)	21.22±2.25	22.48±2.04
MCHC (%)	42.54±1.24	42.44±1.11
HT (%)	40.12±2.09	41.22±1.24
Lymphocytes (%)	44±2.9	46±2.22
Monocytes (%)	3±0.1.22	4±0.12
Heterophils (%)	45±2.60	42±2.32

Values are mean ± SEM; n=6 in each group, AAE was compared with control group showed non- significant results.

Table: 4 Results of the biochemical parameters of AAE(1000 mg/kg/oral) in rats.

BIOCHEMICAL PARAMETERS	Control	AAE (1000 mg/kg/oral)
Albumin (g/dl)	3.7±0.5	4.11±0.88
Alkaline Phosphates (U/l)	86.24±2.4	64.11±1.4*
Creatinine (mg/dl)	0.6±0.05	0.7±0.14
Cholesterol (mg/dl)	72.04±0.14	139.24±2.47
Glucose (mg/dl)	90.24±3.47	72.54±2.45*
GGT (U/l)	43.74±1.33	44.57±1.74
LDH (U/l)	136.45±5.8	142.45±2.64
SGOT (U/l)	68.24±4.2	67.13±2.24
SGPT (U/l)	26.14±1.74	28.46±1.4
Urea (mg/dl)	21.54±1.13	24.21±1.03
Uric acid (mg/dl)	5.24±0.44	6.24±1.04
Total bilirubin (mg/dl)	0.62±0.05	0.68±0.02

Total Protein (g/dl)	6.24±0.98	6.29±1.02
Triglycerides (mg/dl)	134.72±4.4	147.11±3.1

Values are mean ± SEM; n=6 in each group AAE were compared with control group albumin, creatinine, GGT, LDH, SGOT, SGPT, urea, uric acid, total bilirubin and total protein values were not altered significantly ALP, glucose values were significantly less and cholesterol level was significantly high. (*= P<0.05 significant).

Table: 5 Results of serum hormonal parameters of AAE(1000 mg/kg/oral) treated rats.

Sl. No	Groups	Oestradiol (Pg/ml)	Progesterone (Pg/ml)	Triiodothyronine (µU/ml)	Thyroxin (µU/ml)	Thyroid stimulating hormone (µU/ml)
1	Group-I (Control)	69.37±2.15	13.13±0.94	0.33 ± 0.11	1.28 ± 0.11	67.09 ± 1.12
2	Group-II (AAEtreated)	24.35±1.24**	07.24±0.17*	0.37 ± 0.17	1.47 ± 0.13	69.28 ± 1.57

Values are mean ± SEM; n=6 in each group AAE were compared with control group. Triiodothyronine, thyroxin, thyroid stimulating hormone values were not altered significantly while oestradiol, progesterone values were significantly less. (**= P<0.01) moderately significant, (*= P<0.05 significant).

Table-6 Results of tissue weight analysis of AAE(1000 mg/kg/oral)treated rats.

Sl.No	Groups	Brain (g)	Heart (g)	Kidney(g)	Liver(g)	Uterus(g)
1.	Group-I (Control)	1.612±0.09	0.457±0.04	0.987±0.02	3.07±0.09	0.535±0.01
2.	Group-II (AAEtreated)	1.597±0.08	0.547±0.05	0.898±0.04	3.14±0.1	0.347±0.11*

Values are mean ± SEM; n=6 in each group AAE were compared with control group brain, heart, kidney, liver values were not altered significantly uterus values was significantly less (*= P<0.05 significant).

RESULTS OF MACROSCOPIC ANALYSIS

Table-7.14: Results of macroscopic analysis of AAE(1000 mg/kg/oral) treated rats.

Sl.No	Groups	Brain (g)	Heart (g)	Kidney(g)	Liver(g)	Uterus(g)
1.	Group-I (Control)	N	N	N	N	N
2.	Group-II (AAE treated)	N	N	N	N	AbN

N= Normal; Ab N = abnormal

HISTOPATHOLOGICAL RESULTS OF AAE(1000 mg/kg/oral) TREATED RATS - Photomicrograph of sections (H&E staining, magnificationX10)

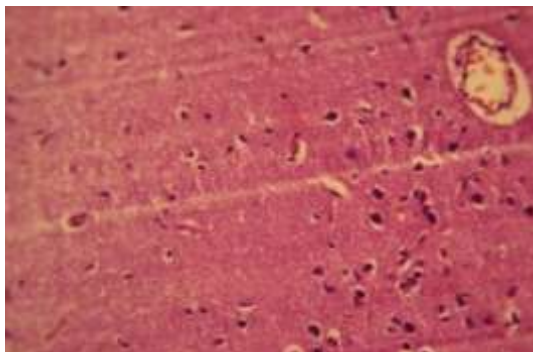


Fig- 1: Tween 80 (2%) 1 ml/ kg/p.o treated brain cells of rats.

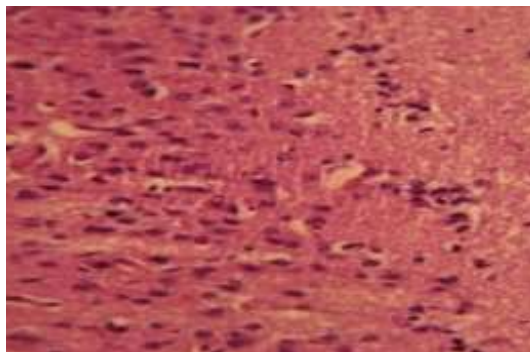


Fig-2: AAE treated brain cells of rats.

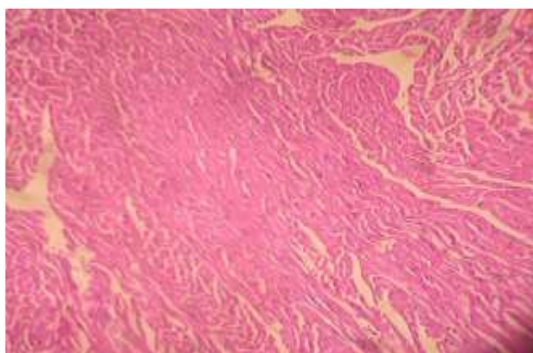


Fig-3: Tween 80 (2%) 1 ml/ kg/p.o treated cardiac muscle of rats.

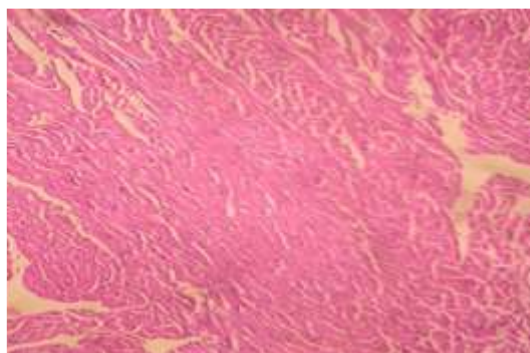


Fig-4 AAE treated cardiac muscle of rats.

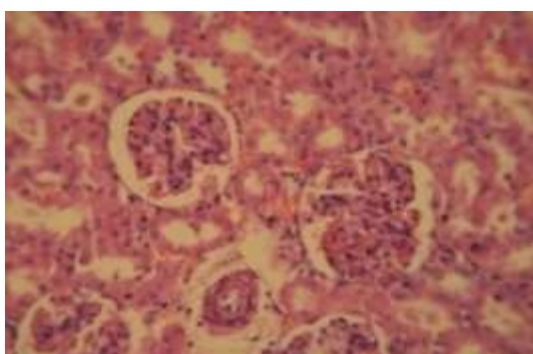


Fig-5 Tween 80 (2%) 1 ml/ kg/p.o treated kidney cells of rats.

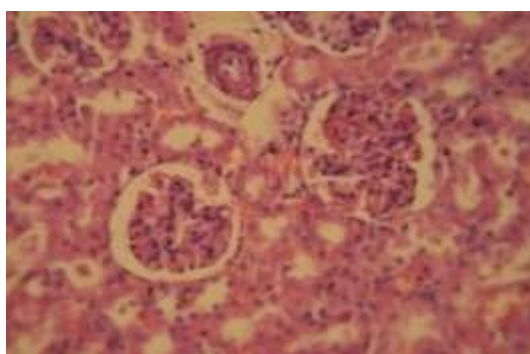


Fig-6: AAE treated kidney cells of rats.

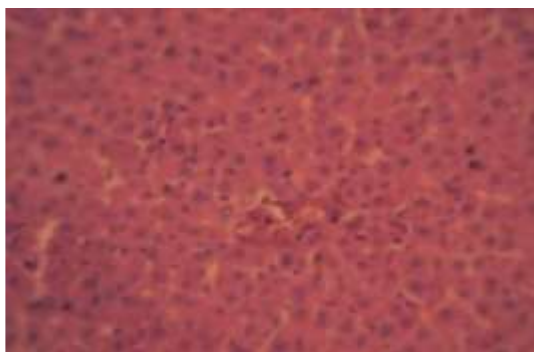


Fig-7: Tween 80 (2%) 1 ml/ kg/p.o treated liver cells of rats.

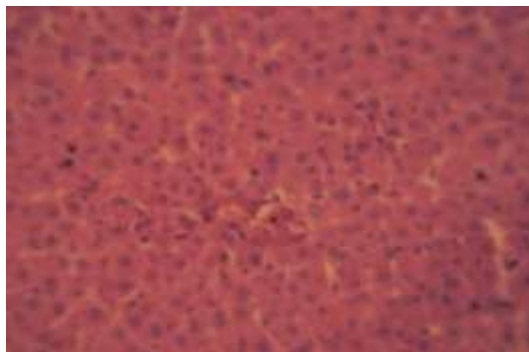


Fig-8: AAE treated liver cells of rats.

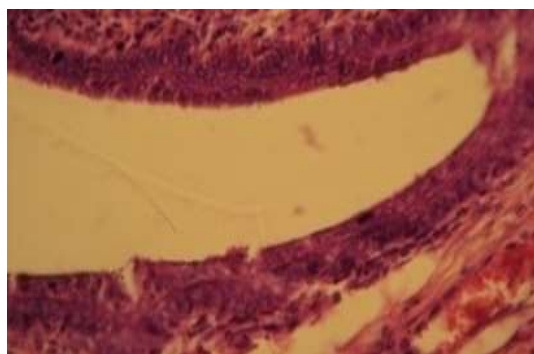


Fig-9: Tween 80 (2%) 1 ml/ kg/p.o treated uterus cells of rats.

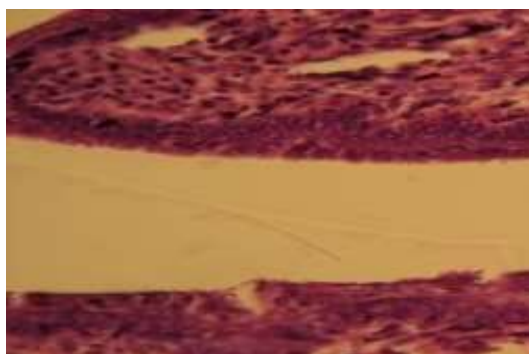


Fig-10: AAE treated uterus cells of rats.

Results of Sub-Acute Toxicological Study:

Repeated dose 28-days oral toxicity study was performed in adult female young virgin Wistar rats and the gross behavioural studies were observed after administering AAE at a dose of 1000mg/kg/oral and the spontaneous motor activity, effect on reflexes, effect on autonomic nervous system and effect after manipulations parameters were observed visually. The effects of drugs on the central and peripheral nervous systems can be easily recognized in normal animals. Several neurological and neuropsychological tests are described which can be used as first screen for behaviour abnormalities in mice or rats. Some of the plant extract contains potent drugs may act on ANS and CNS results in an increase or decrease activity in motor nerves which may alter the behavioural changes.

Repeated dose 28-days oral toxicity study of the test compound AAE at 1000 mg/kg/oral does not altered the normal behaviour such as ataxic gait, bizarre behaviour, grooming behaviour, lying flat on the back, lying flat on the belly, lying flat on the side, narcosis, restlessness, sleeping, straub's phenomenon, timidity and also absence of chronic convulsions, opisthotonus, rolling and jumping, tonic convulsions, tremors, twitches and writhing. The results were compared with control animals and found to be normal (Table: 2). Further corneal reflexes, pain following stimulation and pinna reflex were also normal. Effect on autonomic nervous system such as cyanosis, defecation, eyelids (closure/exophthalmus), lacrimation, piloerection, pupil diameter (constriction /dilatation), salivation, secretion of sweat and urination were normal when compared to control group animals. Effect after manipulations such as auditory stimulus response, escape after touch, writhing reflex, paralysis of hind & fore paws and catalepsy in induced position were not observed. All the above parameters proved that the repeated dose 28-days oral toxicity study in rats after

administering AAE at a dose of 1000mg/kg/oral respectively were safe and did not alter the normal behaviour of the treated rats.

The hematological parameters such as WBC count, RBC count, haemoglobin, MCV, MCH, MCHC, HT, lymphocytes, monocytes and heterophils the results were not altered significantly when compared to control group animals (Table:3). Serum biochemical parameters such as albumin, creatinine, GGT, LDH, SGOT, SGPT, urea, uric acid, total bilirubin and total protein were not altered significantly when compared to control group animals. The level of ALP, glucose were less and cholesterol level was very high and the results were found statistically significant when compared to control group animals (Table:4). The hormonal levels of oestrogen, progesterone were altered significantly and the T3, T4 and TSH levels were not altered. The histopathological results supported the above findings (Table: 5).

The histopathological slides of brain 1000 mg/kg/oral treated rat showed normal cellular architecture of neurons and glial cells, conforms the safety of AAE when compared to normal group cells of brain (Fig:1-2). The histopathological slides of myocardium 1000 mg/kg/oral treated rat showed the normal architecture, absence of oedema, nuclear fatty infiltration, inflammatory cells with normal architecture of myocardial fibres were seen which confirms the safety of AAE when compared to normal group cells (Fig:3-4).

The histopathological slides of kidney 1000 mg/kg/oral treated rat showed normal cellular architecture showed normal cellular architecture of kidney pattern of glomeruli and tubular cells, conforms the safety of AAE when compared to normal group cells of kidney (Fig:5-6). The histopathological slides of liver 1000 mg/kg/oral treated rat hepatic cells has sinusoidal space, central vein showing normal architecture, absence of disarrangement, degeneration of hepatic cells, necrosis, sinusoidal haemorrhages and dilatations; conforms the safety of AAE when compared to normal group cells of liver (Fig:7-8). The histopathological slides of uterus 1000 mg/kg/oral treated rat showed normal uterus cells with prominent epithelium lining, conforms the safety of AAE when compared to normal group cells of uterus (Fig: 9-10).

Conclusion:

In summary, repeated oral doses of ethanolic extract of *Achyranthes aspera* L., in wistar rats to rats for 28 days resulted in devoid of abnormalities in the hematological parameters, gross behavior studies, macroscopic analysis, serum hormonal parameters, biochemical parameters. Further the assessment of histopathology of hepato, renal and cardiac are devoid of toxicity in nature. The no observed adverse effect level of ethanolic extract of *Achyranthes aspera* L was estimated to be 1000 mg/kg per day. The study provides scientific evidence for the future studies in *Achyranthes aspera* L.

Acknowledgement:

The author wish to thank Mr. .M. Gurumani, who has helped in the research.

Reference:

1. Alagesabooopathi C. Endemic Medicinal Plants. MJP Publisher; 2019 Jun 11.
2. Zalavadiya VI, Shah VK, Santani DD, Patel MS, Fosi JM, Chaudhary AK. *Achyranthes aspera*-Plant with high Medicinal Important. Research Journal of Pharmacology and Pharmacodynamics. 2013;5(4):266-72.
3. Srivastav S, Singh P, Mishra G, Jha KK, Khosa RL. *Achyranthes aspera*-An important medicinal plant: A review. J Nat Prod Plant Resour. 2011;1(1):1-4.
4. Zalavadiya VI, Shah VK, Santani DD, Patel MS, Fosi JM, Chaudhary AK. *Achyranthes aspera*-Plant with high Medicinal Important. Research Journal of Pharmacology and Pharmacodynamics. 2013;5(4):266-72.
5. Jadav HR, Ruknuddin G, Prajapati PK, Harisha CR. Pharmacognostical study on flowers and fruits of *Apamarga* (*Achyranthes aspera* Linn.). International Journal of Green Pharmacy (Medknow Publications & Media Pvt. Ltd.). 2013 Apr 1;7(2).
6. OECD (2008), Test No. 407: Repeated Dose 28-day Oral Toxicity Study in Rodents, OECD Guidelines for the Testing of Chemicals, Section 4, OECD Publishing, Paris, <https://doi.org/10.1787/9789264070684-en>.

7. H. Gerhard Vogel, Wolfgang H. Vogel(eds) 'Drug Discovery and Evaluation' ;1997.
8. Ofem OE, Ani EJ, Eno AE. Effect of aqueous leaves extract of *Ocimum gratissimum* on hematological parameters in rats. *International Journal of Applied and Basic Medical Research*. 2012 Jan;2(1):38.
9. Kucukkurt I, Akbel E, Karabag F, Ince S. The effects of dietary boron compounds in supplemented diet on hormonal activity and some biochemical parameters in rats. *Toxicology and industrial health*. 2015 Mar;31(3):255-60.
10. Zaid SS, Sulaiman SA, Sirajudeen KN, Othman NH. The effects of Tualang honey on female reproductive organs, tibia bone and hormonal profile in ovariectomised rats-animal model for menopause. *BMC complementary and alternative medicine*. 2010 Dec;10(1):1-7.
11. Shinoda M, Latour MG, Lavoie JM. Effects of physical training on body composition and organ weights in ovariectomized and hyperestrogenic rats. *International journal of obesity*. 2002 Mar;26(3):335-43.
12. Shinde UA, Goyal RK. Effect of chromium picolinate on histopathological alterations in STZ and neonatal STZ diabetic rats. *Journal of cellular and molecular medicine*. 2003 Jul;7(3):322-9.